

# Case report: Parasitism of *Ornithonyssus bursa* (Macronyssidae) in humans in the Taquari River Valley region, southern Brazil

Reporte de caso: parasitismo de *Ornithonyssus bursa* (Macronyssidae) en humanos en la región del valle del río Taquari, sur de Brasil

Aline Marjana Pavan<sup>1\*</sup>, Darliane Evangelho-Silva<sup>1</sup>, Luiz Liberato Costa-Corrêa<sup>2</sup>, Noeli Juarez Ferla<sup>1</sup>

## Abstract

*Ornithonyssus bursa* hematophagous mite whose main host is wild and domestic birds, which can temporarily parasitize humans in the absence of the main host. Infestations occur when birds abandon nests or direct contact with infected birds. The specimens were collected in a house in the urban area, with the help of a paper towel and kept under low refrigeration for later identification. The mites were identified as *O. bursa*, considered an important poultry pest. The present report is the first case of hematophagous parasitism in humans in the region of Vale do Taquari, Rio Grande do Sul, Brazil.

**Keywords:** bites, birds, dermatitis, mites

## Resumen

*Ornithonyssus bursa* es un ácaro hematófago que se encuentra comúnmente en aves silvestres y domésticas y podría parasitar temporalmente a los humanos. Las infestaciones en humanos ocurren cuando cualquiera de las aves abandona sus nidos. Los especímenes fueron recolectados en una residencia en el área urbana del municipio de Cruzeiro do Sul con la ayuda de una toalla de papel y mantenidos a baja refrigeración para su montaje e identificación. Los ácaros se identificaron como *O. bursa*, que se considera una plaga aviar importante. Este es el primer reporte de parasitismo en humanos por este ácaro en la región del Valle del Río Taquari, Rio Grande do Sul, Brasil.

**Palabras claves:** ácaros, aves, dermatitis, picaduras

<sup>1</sup>. Tecnovates, Universidade do Vale do Taquari - Univates, Laboratório de Acarologia, Lajeado, RS, Brasil.

<sup>2</sup>. Universidade do Vale do Rio dos Sinos, Laboratório de Ornitologia e Animais Marinhos, São Leopoldo, RS, Brasil.

\* Corresponding author: <alinemarjana@gmail.com>



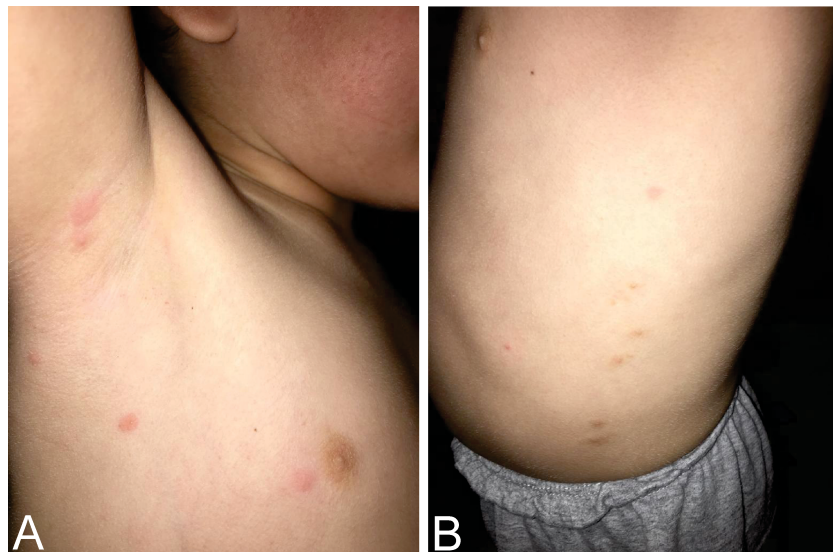
Found in tropical and subtropical regions, *Ornithonyssus bursa* (Berlese, 1888) (Acari: Macronyssidae) is a hematophagous mite that parasitizes domestic and wild birds (Arce et al., 2018; Mascarenhas et al., 2009). It is generally found around the peak and eyes, where it feeds on the birds blood (Mascarenhas et al., 2009), and it reaches high infestation rates, which causes anemia and might even lead to death (Guimarães et al., 2001; Lareschi et al., 2017). It can also be found in nests of wild birds, both in urban and rural settings. This mite species has already been reported in bird species of the families Strigidae (Mascarenhas et al., 2009), Tinamidae, Charadriidae, Columbidae, Furnariidae, Hirundinidae, Icteridae, Mimidae, Passerellidae, Tyrannidae, and Thraupidae (Oliveira et al., 2012). However, it can be found in other wild birds. In the absence of its primary host, it migrates to residences, causing allergies in their inhabitants. Its bite causes pruritus and temporary skin lesions (Arce et al., 2018; Mentz et al., 2015; Oliveira et al., 2012).

In Brazil, *O. bursa* was first reported parasitizing humans in the 1990's in southern Brazil (Mentz et al., 2015; Oliveira et al., 2012; Sarda-Ribeiro et al., 1992). Humans are generally infested either through nests that are abandoned after nidification or by handling infested birds (Bassini-Silva et al., 2019),

regardless of age, humans become susceptible by acting as an alternative food source for the mites, which can occur in both urban and rural areas. The present study reports a new event of infestation by *O. bursa* in humans in an urban environment, in the South of Brazil.

The present case occurred in December 2020, in the urban area of the municipality of Cruzeiro do Sul, Taquari River Valley region, state of Rio Grande do Sul, Brazil. A three-year-old child presented some skin lesions characterized as erythematous papules (figure 1) in their back and arms, followed by intense pruritus staying for approximately for about 10 days in the body. The presence of *O. bursa* was observed in several parts of the residence, e.g. bed, bedroom, walls, and wardrobe. A nest of *Zenaida auriculata* (Des Murs, 1847) (Columbiformes, Columbidae) was found in the air-conditioner beside the bedroom window.

Mites were collected with the help of paper towel, stored in plastic bags, and subsequently sent to Laboratório de Acarologia of Universidade do Vale do Taquari - Univates, Lajeado, state of Rio Grande do Sul. Samples were maintained under low refrigeration 8 °C for subsequent mounting. A total of 20 specimens were mounted in Hoyer's medium and main-



**Figure 1.** A. Skin lesion caused by the hematophagous *O. bursa* in the axillary region. B. Skin lesion caused by hematophagous *O. bursa* on the side of the abdomen.

tained in a furnace with temperature between 50–60 °C for approximately ten days for drying, fixating, distending, and clarification of the specimens (Silva et al., 2018). Specimens were identified using a Leica S6E optical microscope with 2500 LED and phase contrast according to Guimarães et al. (2001).

Morphologically *O. bursa* is very similar to *O. sylviarum*, however, the distinction between species is found mainly in the sternal shield, where it contains the third pair of arrows (figure 2D). It presents a tapered genitoventral shield in the posterior region (figure 2B), and a dorsal shield gradually decreases at the distal end (figure 2A) with smaller arrows, it presents a chelicera in the shape of a chela (figure 2C) (Guimarães et al., 2001).

*Ornithonyssus bursa* parasitizes humans in the absence of their food source; this indicates that they temporarily become parasites since they cannot complete their cycle (reproduce) and that they live for long periods of time away from birds, considered as their main hosts (Orton et al., 2000). In the present study, the infestation of this hematophagous mite towards the child was probably opportunistic, due to the recent abandonment of the chicks to the nest, which forced the transfer of the *O. bursa* to another

food source. Therefore, infestations of this mite in residences only occur when conditions are favorable for its reproduction and propagation (Oliveira et al., 2012).

The presence of *O. bursa* on humans in Brazilian territory has been reported in the southern and southeastern regions, associated with warmer seasons of the year (Mentz et al., 2015; Mesquita-Sousa et al., 2020; Sarda-Ribeiro et al., 1992), which is corroborated by the present study. Avian-mite lesions caused on the child were located mostly in the arms, like previous reports (Oliveira et al., 2012; Suzuki et al., 2014). Attacks on humans are usually more frequent in rural areas, especially in poultry farmers, as these mites are considered to attain pest status in the poultry chain where they act as a potential vector of the arbovirus (Santillán et al., 2015). However, hematophagous mite infestations have occurred more frequently in urban areas due to the proliferation of pigeons due to the construction of their nests on roofs or air conditioning (Suzuki et al., 2014), as birds are the main hosts of several species of hematophages (Bassini-Silva et al., 2019).

Air-conditioners or eaves in residences might serve as shelters for birds to build their nests, thus increasing

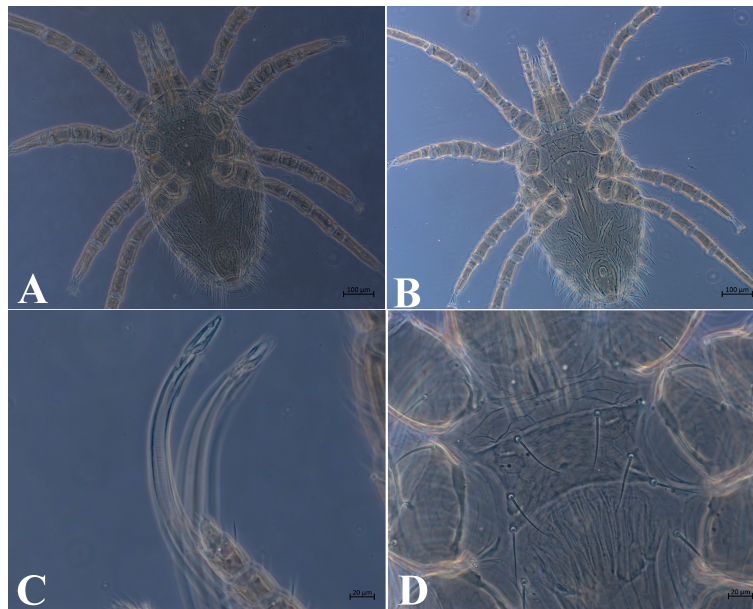


Figure 2. *Ornithonyssus bursa*. A. Dorsal view. B. Ventral view. C. Chelicera. D. Sternal plate.

the frequency of cases. However, avian-mite dermatitis is generally misdiagnosed as bites from other arthropods (Waap et al., 2020). Although there are no reports on the transmission of pathogens (Bassini-Silva et al., 2019), the presence of bacteria of the genus *Wolbachia* associated with this mite species has already been reported (Lareschi et al., 2017). Therefore, it is necessary that dermatologists— and especially general practitioners— become familiar with gamasoidosis, popularly known as avian-mite dermatitis. Dermoscopy criteria to identify dermatitis caused by hematophagous mites have yet to be described in medical literature (Suzuki et al., 2014; Wambier and Wambier, 2012). These definitions might help establish an accurate diagnosis and hence find a suitable treatment.

## ACKNOWLEDGEMENTS

We thank the University of Vale do Taquari - Univates for providing all the necessary material during the study, and the National Council for Scientific and Technological Development (CNPq) for the research productivity grant awarded to Noeli Juarez Ferla (Process n° 313658 / 2020- 0). Authors were supported by the Coordenação de Aperfeiçoamento de Pessoal de Nível Superior (CAPES) and Naturovos.

## CONFLICT OF INTEREST

The authors declare no conflict of interest.

## REFERENCES

- Arce, S. I., Saravia-Pietropaolo, D. E., Quiroga M. A., Antoniazzi, L. R., Lareschi, M., & Beldomenico, P. M. (2018). The tropical fowl mite, *Ornithonyssus bursa* (Acari: Macronyssidae): Environmental and host factors associated with its occurrence in Argentine passerine communities. *Parasitology Research*, 117(10), 3257–3267. doi.org/10.1007/s00436-018-6025-1.
- Bassini-Silva, R., Jacinavicius, F. D. C., Hernandez, F. A., Ochoa, R., Bauchan, G. R., Dowling, A. P., & Barros-Battesti, D. M. (2019). Dermatitis in humans caused by *Ornithonyssus bursa* (Berlese 1888) (Mesostigmata: Macronyssidae) and new records from Brazil. *Revista Brasileira de Parasitologia Veterinária*, 28, 134–139. doi.org/10.1590/S1984-296120180097.
- Guimarães, J. H., Tucci, E. C., Barros-Battesti, D. M. (2001). *Ectoparasitos de importância veterinária*. FAPESP.
- Lareschi, M., Cicuttin, G. L., Salvo, M. N. D., Ibañez, L., & Montalti, D. (2017). The tropical fowl mite *Ornithonyssus bursa* (Acari: Mesostigmata: Macronyssidae) parasitizing the European starling *Sturnus vulgaris* (Aves: Passeriformes: Sturnidae), an invasive bird in central Argentina. An approach to the bacterial fauna of this mite. *Revista Mexicana de Biodiversidad*, 88(2), 454–458. doi.org/10.1016/j.rmb.2017.03.022.
- Mascarenhas, C. S., Coimbra, M. A., Müller, G., Brum, J. G. W. (2009). Ocorrência de *Ornithonyssus bursa* (Berlese, 1888) (Acari: Macronyssidae) em filhotes de *Megascops choliba* (corujinha-do-mato) e *Pitangus sulphuratus* (bem-te-vi), no Rio Grande do Sul, Brasil. *Revista Brasileira de Parasitologia Veterinária*, 18(4), 69–70. doi.org/10.4322/rbvp.01804013.
- Mentz, M. B., Silva, G. L. D., & Silva, C. E. (2015). Dermatitis caused by the tropical fowl mite *Ornithonyssus bursa* (Berlese) (Acari: Macronyssidae): A case report in humans. *Revista da Sociedade Brasileira de Medicina Tropical*, 48(6), 786–788. doi.org/10.1590/0037-8682-0170-20.
- Mesquita-Sousa, D., Viegas-Melo, D., Martins, T. F., Monteiro, S. G., Faccini, J. L., Labruna, M. B., Barros-Battesti, D. M., Bassini-Silva, R., Soares, A. M. S., Costa-Junior, L. M., & Luz, H. R. (2020). An overview of gamasoidosis caused by *Ornithonyssus bursa* (Mesostigmata: Macronyssidae) in Brazil and new case records. *International Journal of Acarology*, 46(7), 568–573. doi.org/10.1080/01647954.2020.1810119.
- Oliveira, C. B., Tonin, A. A., & Monteiro, S. G. (2012). Parasitismo do ácaro *Ornithonyssus bursa* em humanos no Sul do Brasil. *Acta Scientiae Veterinariae*, 40(4), 1–3. <https://www.redalyc.org/articulo.oa?id=289023924026>
- Orton, D. I., Warren, L. J., & Wilkinson, J. D. (2000). Avian mite dermatitis. *Clinical and Experimental Dermatology*, 25(2), 129–131. doi.org/10.1046/j.1365-2230.2000.00594.x.
- Santillán, M. Á., Grande, J. M., Liébana, M. S., Martínez, P., Diaz, L. A., Bragagnolo, L. A., Solaro, C., Galmes, M.A., & Sarasola, J. H. (2015). New hosts for the mite *Ornithonyssus bursa* in Argentina. *Medical and Veterinary Entomology*, 29(4), 439–443. doi.org/10.1111/mve.12129.
- Sarda-Ribeiro, V. L., Moojen, V., & Dutra Telles, A. P. (1992). *Ornithonyssus bursa*: parasito de aves causando acaríases cutâneas em humanos no Rio Grande do Sul, Brasil. *Anais Brasileiros de Dermatologia*, 67(1), 31–34. <http://www.anaisdedermatologia.com.br/detalhe-artigo/938/Ornithonyssus-bursa-parasito-de-aves-causando-acaríases-cutâneas-em-humanos-no-Rio-Grande-do-Sul-Brasil>
- Silva, D. E., Da Silva, G. L., Do Nascimento, J. M., & Ferla, N. J. (2018). Mite fauna associated with bird nests in Southern Brazil. *Systematic and Applied Acarology*, 23(3), 426–440. doi.org/10.11158/saa.23.3.2.
- Suzuki, C. M. P., Stolf, H. O., Camargo, R. M. P. D., & Haddad Jr., V. (2014). Gamasoídose ou dermatite por ácaros aviários: relato de caso. *Diagnóstico & Tratamento*, 19, 74–6. <http://files.bvs.br/upload/S/1413-9979/2014/v19n2/a4140.pdf>
- Waap, H., Aguin-Pombo, D., & Maia, M. (2020). Case re-



port: Human dermatitis linked to *Ornithonyssus bursa* (Dermanysoidea: Macronyssidae) infestation in Portugal. *Frontiers in Veterinary Science*, 7, 1093. <https://doi.org/10.3389/fvets.2020.567902>

Wambier, C. G., & Wambier, S. P. d. F. (2012). Gamasoidosis illustrated—from the nest to dermoscopy. *Anais Brasileiros de Dermatologia*, 87(6), 926–927. <https://doi.org/10.1590/s0365-05962012000600021>