

Intimal sarcoma of the pulmonary artery presenting as pulmonary embolism

María Camila Plata¹, Diana Lucía Rey², Claudio Villaquirán², Diego Rosselli¹

SUMMARY

Pulmonary artery sarcomas are extremely rare; due to their insidious growth, diagnosis occurs late and prognosis is poor. We present the case of a 33-year-old woman with a history of dyspnea, chest pain and syncope. An obstructing mass on the right ventricle, main pulmonary artery and right branch were interpreted as a possible pulmonary embolism.

KEY WORDS

Diagnosis; Differential; Pulmonary Artery; Pulmonary Embolism; Sarcoma

RESUMEN

Sarcoma de la íntima de la arteria pulmonar que se presentó como embolismo pulmonar

Los sarcomas de la arteria pulmonar son extremadamente raros; debido a su crecimiento lento y silencioso, el diagnóstico suele ser tardío y son de mal pronóstico. Presentamos el caso de una mujer de 33 años de edad con historia de disnea, dolor torácico y síncope. Una masa que obstruía el ventrículo derecho, el tronco pulmonar y la arteria pulmonar derecha llevó a la sospecha de embolismo pulmonar.

PALABRAS CLAVE

Arteria pulmonar; Diagnóstico Diferencial; Embolismo pulmonar; Sarcoma

¹ Clinical Epidemiology and Biostatistics Department, Pontificia Universidad Javeriana, Medical School, Bogotá, Colombia.

² Respiratory Diseases Unit, Internal Medicine Department, Hospital Universitario San Ignacio, Pontificia Universidad Javeriana, Medical School, Bogotá, Colombia.
Correspondencia: Diego Rosselli; diego.rosselli@gmail.com

Recibido: julio 12 de 2016

Aceptado: octubre 5 de 2016

Cómo citar: Plata MC, Rey DL, Villaquirán C, Rosselli D. Intimal sarcoma of the pulmonary artery presenting as pulmonary embolism. *Iatreia*. 2017 Jul-Sept;30(3): 340-343. DOI 10.17533/udea.iatreia.v30n3a10.

RESUMO

O sarcoma da íntima da artéria pulmonar, que se apresentou como um quadro de embolia pulmonar

Os sarcomas da artéria pulmonar são extremamente raros devido ao seu crescimento lento e silencioso, o diagnóstico normalmente é tardio e são de mal prognóstico. Apresentamos um caso de uma mulher de 33 anos de idade com história de dispneia dor torácica e desmaios. Uma massa que obstruía o ventrículo direito, tronco pulmonar e artéria pulmonar direita levou à suspeita de embolia pulmonar

PALAVRAS CHAVE

Artéria Pulmonar; Diagnóstico Diferencial; Embolia Pulmonar; Sarcoma

CASE REPORT

A 33-year-old woman was admitted with pleuritic chest pain, a febrile episode of 38.5 °C and several

days of progressive dyspnea. Her medical history was unremarkable, except for occasional shortness of breath and two syncopal episodes associated with exercise. Low blood pressure (80/60 mm Hg), tachycardia (100 beats per minute) and a systolic heart murmur along the left upper edge of the sternum were found on physical examination.

She had sinus tachycardia on electrocardiography, higher values of serum dimerized plasmin fragment D (D-dimer) (5000 ng/mL) and an enlarged pulmonary artery with mild cardiomegaly on the chest X-ray. The cardiac ultrasonographic study showed a 5.5 cm x 2.4 cm mass on the out-flow tract of the right ventricle, occluding 85 % of the main pulmonary artery and causing pulmonary valve insufficiency and pulmonary hypertension (systolic pulmonary pressure of 55 mm Hg). The CT scan revealed a large filling defect with little enhancement, which obstructed the main pulmonary artery and its right branch, with heart involvement and moderate pericardial effusion (figure 1).

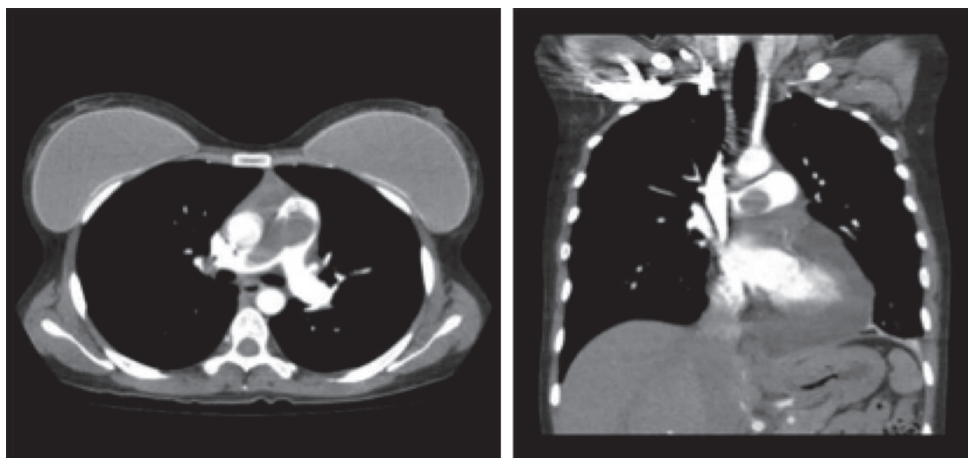


Figure 1. CT scan shows heart involvement, moderate pericardial effusion, and filling defect obstructing the main pulmonary artery and right branch

An acute pulmonary embolism was initially considered, and anticoagulation with thrombolytic therapy was suggested. However, some clinical symptoms (a few months with dyspnea and syncope) and findings (pulmonary hypertension) could not be explained by an acute pulmonary embolism. A chronic

thromboembolic pulmonary hypertension could explain both, but the absence of previous deep vein thrombosis, and medical pro-thrombotic conditions, as well as the absence of typical radiological features (pouch defects, webs, bands, intimal irregularities, lobar or segmental involvement), were arguments

against it. Her symptoms, ultrasonographic findings, mild contrast enhancement of the mass, apparent myocardial involvement, and pericardial effusion, suggested a neoplastic origin.

The patient was taken to surgery, but a complete resection was not possible, due to extensive myocardial and pericardial involvement; only biopsies

were taken. Histopathologic examination revealed areas of necrosis, large round cells, eosinophilic cytoplasm, pleomorphic nuclei and atypical mitoses. Immunohistochemical findings were consistent with an intimal sarcoma of the pulmonary artery (figure 2). After the intervention, the patient started neoadjuvant chemotherapy and was last seen seven months later.

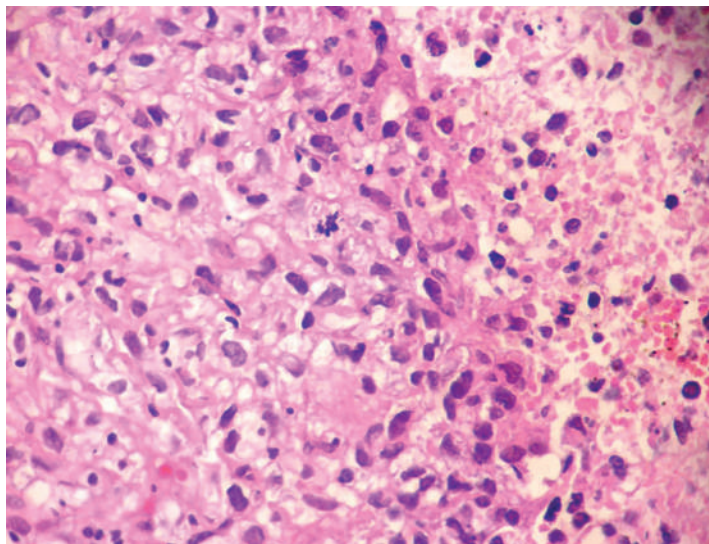


Figure 2. Necrosis, large round cells, eosinophilic cytoplasm, pleomorphic nuclei and atypical mitoses (hematoxylin and eosin, X 400)

COMMENT

Primary neoplasms of the pulmonary circulation are extremely rare. Pulmonary artery sarcoma is a rare tumor that often is mistaken for pulmonary thrombus, due to the similarities of their signs and symptoms; both can progress to pulmonary hypertension and both have similar radiological findings. This normally leads to a delayed diagnosis (1-3). After the first case reported by Mandelstamm in 1923, a few cases have been described, mostly on autopsy. Mean age of presentation has been around fifty years, with a slight preference for females (1.3 to 1) (4). According to World Health Organization (WHO), there are three types of sarcoma of large blood vessels: angiosarcoma, leiomyosarcoma and intimal sarcoma (3). Intimal sarcomas have a predominant intraluminal polypoid growth pattern,

often obstructing the lumen of the vessel of origin (2). Yet the clinical presentation is variable; patients usually have a long asymptomatic course. Symptoms like chest pain, dyspnea, cough, pre-syncope and syncope are non-specific and usually the result of an obstructive phenomenon, while fever, weight loss, anemia, hemoptysis, clubbing and increased erythrocyte sedimentation rate are associated with the neoplastic behavior. On physical examination a systolic heart murmur over the pulmonary valve, and signs of right heart failure can be found. Because of the nonspecific symptoms and rarity, many cases are misdiagnosed as pulmonary thromboembolism and treated inappropriately (1). The absence of deep venous thrombosis, negative results of procoagulant changes and the lack of response to anticoagulant therapy should be valued (3).

Chest X-ray may be normal or may show cardiomegaly, pulmonary hypertension, hilar enlargement, infiltrates, nodules or cavitations (4). Echocardiographic findings include right ventricle enlargement, pulmonary hypertension, and obstruction of outflow tract, main pulmonary artery or branches by a pedunculated mass (4-6). Filling defects on CT scan are similar to those of acute or chronic thromboembolism, with or without nodules, or with a mosaic pattern as result of tumor emboli. Yi and colleagues (7) have reported that CT findings favor the diagnosis of pulmonary artery sarcoma when they include low-attenuation filling defect occupying the entire luminal diameter of the proximal or main pulmonary artery, usually accompanied by expansion of the involved arteries or extraluminal tumor extension (1-3,7). Gadolinium-enhanced MRI has been described as the most useful method for diagnosis, showing enhancement of the intra-luminal mass due to necrosis, or bleeding (2-4), distinguishing it from pulmonary embolism. PET scan can also differentiate between tumor and acute or chronic thromboembolism, and is useful to follow response to therapy, evaluating tumor metabolic activity (4). Dias and colleagues (8) reported two cases to emphasize the importance of F-fluorodeoxyglucose PET as a non-invasive method for the diagnostic investigation of patients whose presentation on CT of contrast filling defects in the pulmonary artery is atypical for thromboembolism. Treatment is early surgery, preferably with pulmonary endarterectomy, and success depends on the extent of resection. These tumors arise from the intima and rarely extend to the adventitia to invade surrounding structures, so resection might result in complete removal. Because the tumor often involves vital cardiac structures such as the pulmonary valve (30 % of cases), radical surgery resection can be challenging (2). Prognosis, however, is still poor, with mean survival of around 10 months for those who undergo surgery, and 6 weeks for those who do not (4,5).

Neo-adjuvant chemotherapy might shrink the tumor and thereby enable its resection. However, in the event of initial misdiagnosis and severe right ventricular dysfunction requiring immediate surgery, there might not be time for it (2). Adjuvant chemotherapy and radiation therapy are recommended for the eradication of any residual tumor foci (2).

CONFLICTS OF INTEREST

None to declare

BIBLIOGRAFIC REFERENCES

1. El-Sayed Ahmed MM, Aftab M, Al-Najjar RM, de la Cruz KI, Benjamin RS, Hallman CH. Pulmonary artery sarcoma mimicking pulmonary embolism. *Tex Heart Inst J.* 2014 Oct;41(5):515-7. DOI 10.14503/THIJ-13-3735.
2. Coskun U, Sinan UY, Calpar I, Yildizeli B, Yanartas M, Filinte D, et al. Pulmonary artery sarcoma masquerading as chronic pulmonary thromboembolism. *Tex Heart Inst J.* 2014 Oct;41(5):518-22. DOI 10.14503/THIJ-13-3598.
3. Dornas AP, Campos FT, Rezende CJ, Ribeiro CA, Amaral NF, Corrêa Rde A. Intimal sarcoma of the pulmonary artery: a differential diagnosis of chronic pulmonary thromboembolism. *J Bras Pneumol.* 2009 Aug;35(8):814-8.
4. Mattoo A, Fedullo PF, Kapelanski D, Ilowite JS. Pulmonary artery sarcoma: a case report of surgical cure and 5-year follow-up. *Chest.* 2002 Aug;122(2):745-7.
5. Mandel J, Mark EJ. Case records of the Massachusetts General Hospital. Weekly clinicopathological exercises. Case 25-2000. A 69-year-old woman with pleuritic pain and a pulmonary arterial obstruction. *N Engl J Med.* 2000 Aug;343(7):493-500.
6. Furest I, Marín M, Escribano P, Gómez MA, Cortinac J, Blanquer R. [Intimal sarcoma of the pulmonary artery: a rare cause of pulmonary hypertension]. *Arch Bronconeumol.* 2006 Mar;42(3):148-50. Spanish.
7. Yi CA, Lee KS, Choe YH, Han D, Kwon OJ, Kim S. Computed tomography in pulmonary artery sarcoma: distinguishing features from pulmonary embolic disease. *J Comput Assist Tomogr.* 2004 Jan-Feb;28(1):34-9.
8. Dias OM, Lombardi EM, Canzian M, Soares Júnior J, Vieira Lde O, Terra Filho M. 18F-fluorodeoxyglucose positron emission tomography as a noninvasive method for the diagnosis of primary pulmonary artery sarcoma. *J Bras Pneumol.* 2011 Nov-Dec;37(6):817-22. English, Portuguese.