

ABSTRACTS

Hepatocellular carcinoma - Global burden and risk factors

HUBERT E. BLUM¹

Global Burden. Hepatocellular carcinoma (HCC) is one of the most common malignant tumors worldwide and has been recently reviewed ^{1,2}. The incidence ranges from < 10 cases per 100,000 population in North America and Western Europe as well as in Iran, Iraq and India to 50-150 cases per 100,000 population in parts of Africa and Asia (Fig. 1) where HCC is responsible for a large proportion of cancer deaths ³. However, a rise in the incidence of and mortality from HCC, most likely reflecting the increased prevalence of hepatitis C virus (HCV) infection, has recently been observed in most industrialized countries ⁴.

Risk Factors. The major etiologies of HCC are well defined (Table 1) and include among the well known factors an elevated body mass index, especially in men ⁵ as well as diabetes mellitus ⁶ and some of the steps involved in the molecular pathogenesis of HCC have been elucidated in recent years. As for most types of cancer, hepatocarcinogenesis is a multistep process involving different genetic alterations that ultimately lead to malignant transformation of the hepatocyte. While significant progress has been made in recognizing the sequence of events involved in other forms of cancer, most notably in colorectal cancer and certain hematopoietic malignancies, the molecular contribution of the multiple factors and their interactions in hepatocarcinogenesis are still poorly understood. HCCs are phenotypically (morphology, microscopy) and genetically very heterogeneous tumors, possibly reflecting in part the heterogeneity of etiologic factors implicated in HCC development, the complexity of hepatocyte functions and the late stage at which HCCs usually become clinically symptomatic and detectable. Malignant transformation of hepatocytes may occur regardless of the etiologic agent through a pathway of increased liver cell turnover, induced

by chronic liver injury and regeneration in a context of inflammation, immune response and oxidative DNA damage. This may result in genetic alterations, such as the activation of cellular oncogenes, the inactivation of tumor suppressor genes, possibly in cooperation with genomic instability, including DNA mismatch repair defects and impaired chromosomal segregation, overexpression of growth and angiogenic factors, and telomerase activation ⁷⁻¹¹. Chronic viral hepatitis B, C and D, alcohol, metabolic liver diseases such as hemochromatosis and alpha-1-antitrypsin deficiency as well as non-alcoholic fatty liver disease may act predominantly through this pathway of chronic liver injury, regeneration, and cirrhosis. Accordingly, the major clinical risk factor for HCC development is liver cirrhosis since 70-90% of HCCs develop in a cirrhotic liver. Most HCCs occur after many years of chronic hepatitis that provides the mitogenic and mutagenic environment to precipitate random genetic alterations resulting in the malignant transformation of hepatocytes and HCC development.

The HCC risk in patients with liver cirrhosis depends on the activity, duration and the etiology of the underlying liver disease. Clinical and biological variables (age, anti-HCV positivity, PTT and platelet count) allow to further identify a subset of cirrhotic patients with the highest risk of HCC development ¹². Coexistence of etiologies, e. g., hepatitis B virus (HBV) and HCV infection, HBV infection and aflatoxin B1 ^{11,13}, HBV/ HCV infection and alcohol or diabetes mellitus ¹⁴, HCV infection and liver steatosis ¹⁵, environmental factors, e.g., alcohol ^{11, 16, 17} as well as diabetes mellitus, obesity and tobacco ^{5, 17-19} increase the relative risk of HCC development. Also, occult HBV infection (anti-HBc positive only) carries a significant HCC risk ^{20,21}. Interestingly, coffee consumption appears to reduce the HCC risk ²².

.....
¹: Professor, Department of Medicine II, University of Freiburg, Germany. hubert.blum@uniklinik-freiburg.de

In general, HCC are more frequent in males than in females and the incidence increases with age. On the other hand, there is evidence that HBV -and possibly also HCV- may under certain circumstances play an additional direct role in the molecular pathogenesis of HCC. Finally, aflatoxins have been shown to induce mutations of the p53 tumor suppressor gene, thus pointing to the contribution of an environmental factor to tumor development at the molecular level. Further, in a transgenic mouse model it has been shown that chronic immune-mediated liver cell injury without environmental or infectious agents is sufficient to cause HCC²³ and that inhibition of cytotoxic T lymphocyte-induced apoptosis and chronic inflammation by neutralization of the Fas ligand prevents HCC development in this model²⁴. In addition, also in a transgenic mouse model it has been demonstrated that NF-kappaB may be the link between inflammation and HCC development²⁵.²⁶ Finally, individual polymorphisms of drug metabolizing enzymes, e.g., various cytochrome P450 oxidases, N-acetyltransferases and glutathione-S-transferase, may contribute to the genetic susceptibility to HCC development²⁷.

Summary and Perspectives. HCC is one of the most common malignant tumors in some areas of the world with an increasing incidence and an extremely poor prognosis. In order to reduce morbidity and mortality from HCC, therefore, apart from early diagnosis and the development of novel systemic therapies for advanced disease, incl. drugs, gene and immune therapies primary HCC prevention is of paramount importance. Apart from avoiding liver toxins, including alcohol and certain drugs, or infections with HBV or HCV by hygienic measures, avoiding parenteral exposure to blood, blood products or contaminated needles etc. a prime example is vaccination against HBV infection. Universal vaccination in Taiwan has indeed already resulted in a decline of the incidence of HCCs²⁸. Further, early treatment of acute hepatitis aimed at blocking transition into chronic liver diseases well as therapy of chronic liver diseases to prevent their progression to liver cirrhosis should result in a reduced HCC incidence. Finally, in patients with established liver cirrhosis LTx before HCC development is a highly effective preventive measure.

Table 1: Major etiologies of HCC

Chronic Hepatitis B, C and D

Toxins (e.g., alcohol, tobacco, aflatoxins)

Hereditary metabolic liver diseases (e.g., hereditary hemochromatosis, α -1-antitrypsin deficiency)

Autoimmune hepatitis

States of insulin resistance

Overweight in males

Diabetes mellitus

Non-alcoholic steatohepatitis (NASH)

or non-alcoholic

fatty liver disease (NAFLD)

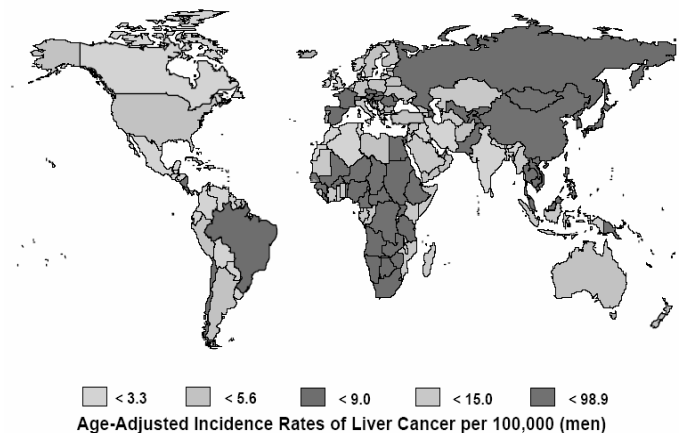


Fig. 1: HCC incidence worldwide

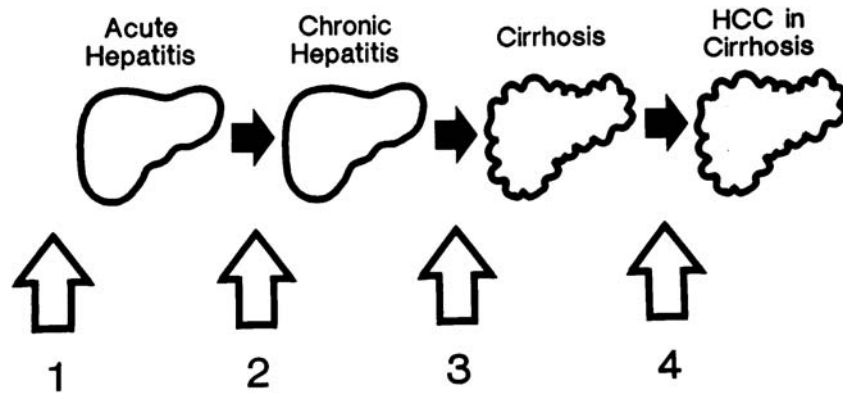


Fig. 2: Primary HCC prevention. (1) Prevention of liver disease, e.g., by hygienic measures, prevention of exposure or vaccination against HBV infection, abstinence from alcohol etc. (2) Prevention of chronic hepatitis: e.g., by treatment of acute hepatitis C, abstinence from alcohol, treatment of hereditary liver diseases etc. (3) Prevention of liver cirrhosis, e.g., by antiviral treatment of chronic hepatitis B or C, treatment of other chronic liver diseases. (4) Prevention of HCC development in liver cirrhosis, e.g., by antiviral treatment, inhibition of fibrosis, liver transplantation etc.

REFERENCES

1. Sherman M, Klein A. AASLD single-topic research conference on hepatocellular carcinoma: Conference proceedings. *Hepatology*, 2004; 40: 1465-1473.
2. Bruix J, Sherman M. Management of hepatocellular carcinoma. *Hepatology*, 2005; 42: 1208-1236.
3. Bosch FX, Ribes J, Diaz M, et al. Primary liver cancer: worldwide incidence and trends. *Gastroenterology*, 2004; 127: S5-S16.
4. El-Serag HB, Davila JA, Petersen NJ, et al. The continuing increase in the incidence of hepatocellular carcinoma in the United States: an update. *Ann Intern Med*, 2003; 139: 817-823.
5. Calle EE, Rodriguez C, Walker-Thurmond K, et al. Overweight, obesity, and mortality from cancer in a prospectively studied cohort of U.S. adults. *N Engl J Med*, 2003; 348: 1625-1638.
6. El-Serag HB. Hepatocellular carcinoma: recent trends in the United States. *Gastroenterology*, 2004; 127: S27-34.
7. Ozturk M. Genetic aspects of hepatocellular carcinogenesis. *Semin Liver Dis*, 1999; 19: 235-242.
8. Suriawinata A, Xu R. An update on the molecular genetics of hepatocellular carcinoma. *Semin Liver Dis*, 2004; 24: 77-88.
9. Satyanarayana A, Manns MP, Rudolph KL. Telomeres and telomerase: a dual role in hepatocarcinogenesis. *Hepatology*, 2004; 40: 276-283.
10. Brechot C. Pathogenesis of hepatitis B virus-related hepatocellular carcinoma: old and new paradigms. *Gastroenterology*, 2004; 127: S56-61.
11. Yu MC, Yuan JM. Environmental factors and risk for hepatocellular carcinoma. *Gastroenterology*, 2004; 127: S72-78.
12. Velazquez RF, Rodriguez M, Navascues CA, et al. Prospective analysis of risk factors for hepatocellular carcinoma in patients with liver cirrhosis. *Hepatology*, 2003; 37: 520-527.
13. Ming L, Thorgerisson SS, Gail MH, et al. Dominant role of hepatitis B virus and cofactor role of aflatoxin in hepatocarcinogenesis in Qidong, China. *Hepatology*, 2002; 36: 1214-1220.
14. Hassan MM, Hwang LY, Hatten CJ, et al. Risk factors for hepatocellular carcinoma: synergism of alcohol with viral hepatitis and diabetes mellitus. *Hepatology*, 2002; 36: 1206-1213.

15. Ohata K, Hamasaki K, Toriyama K, et al. Hepatic steatosis is a risk factor for hepatocellular carcinoma in patients with chronic hepatitis C virus infection. *Cancer*, 2003; 97: 3036-3043.
16. Morgan TR, Mandayam S, Jamal MM. Alcohol and hepatocellular carcinoma. *Gastroenterology*, 2004; 127: S87-96.
17. Marrero JA, Fontana RJ, Fu S, et al. Alcohol, tobacco and obesity are synergistic risk factors for hepatocellular carcinoma. *J Hepatol*, 2005; 42: 218-224.
18. El-Serag HB, Tran T, Everhart JE. Diabetes increases the risk of chronic liver disease and hepatocellular carcinoma. *Gastroenterology*, 2004; 126: 460-468.
19. Caldwell SH, Crespo DM, Kang HS, et al. Obesity and hepatocellular carcinoma. *Gastroenterology*, 2004; 127: S97-103.
20. Yano Y, Yamashita F, Sumie S, et al. Clinical features of hepatocellular carcinoma seronegative for both HBsAg and anti-HCV antibody but positive for anti-HBc antibody in Japan. *Am J Gastroenterol*, 2002; 97: 156-161.
21. Pollicino T, Squadrito G, Cerenzia G, et al. Hepatitis B virus maintains its pro-oncogenic properties in the case of occult HBV infection. *Gastroenterology*, 2004; 126: 102-110.
22. Gelatti U, Covolo L, Franceschini M, et al. Coffee consumption reduces the risk of hepatocellular carcinoma independently of its aetiology: a case-control study. *J Hepatol*, 2005; 42: 528-534.
23. Nakamoto Y, Guidotti L, Kuhlen C, et al. Immune pathogenesis of hepatocellular carcinoma. *J Exp Med*, 1998; 188: 341-350.
24. Nakamoto Y, Kaneko S, Fan H, et al. Prevention of hepatocellular carcinoma development associated with chronic hepatitis by anti-fas ligand antibody therapy. *J Exp Med*, 2002; 196: 1105-1111.
25. Pikarsky E, Porat RM, Stein I, et al. NF-kappaB functions as a tumour promoter in inflammation-associated cancer. *Nature*, 2004; 431: 461-466.
26. Balkwill F, Coussens LM. Cancer: an inflammatory link. *Nature*, 2004; 431: 405-406.
27. Chen CJ, Chen DS. Interaction of hepatitis B virus, chemical carcinogen, and genetic susceptibility: multistage hepatocarcinogenesis with multifactorial etiology. *Hepatology*, 2002; 36: 1046-1049.
28. Chang MH, Chen CJ, Lai MS, et al. Universal hepatitis B vaccination in Taiwan and the incidence of hepatocellular carcinoma in children. Taiwan Childhood Hepatoma Study Group [see comments]. *N Engl J Med*, 1997; 336: 1855-1859.

Hepatocellular carcinoma in cirrhotic liver CT an MRI findings

GERMÁN CASTRILLÓN¹

For all practical purposes, you should consider cirrhosis to be a pre-malignant condition. This means that a patient with cirrhosis is at risk for developing hepatocellular carcinoma (HCC). The greater or lesser risk depends on the etiology of the cirrhosis. There are a lot of complications of cirrhosis, but the most dreaded one is hepatocellular carcinoma. I am going to do a brief review of cirrhosis and then I will talk about the HCC that is the focus of this review.

Imaging the cirrhotic liver is one of the more difficult tasks in radiology. Imaging plays a huge role, regardless of the cause of the cirrhosis and the hepatocellular carcinoma. The first thing that I look for are morphologic changes. Look for nodularity of the liver, signal intensity heterogeneity, and central atrophy. Central atrophy refers to the fact that in many cases of cirrhosis, the anterior segment of the right lobe and the medial segment of the left lobe shrink. This may be accompanied by hypertrophy of the

¹ Assistant Professor, Facultad de Medicina, Grupo de Gastrohepatología, Universidad de Antioquia. germanac@une.net.co