

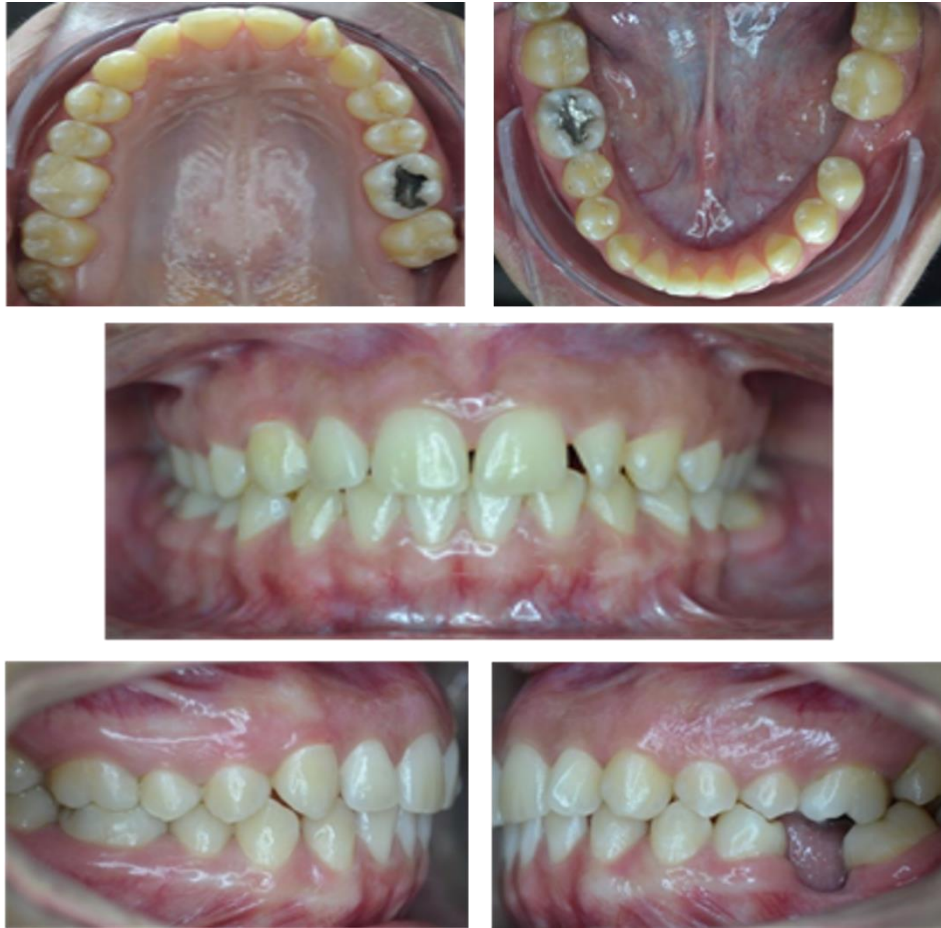

Figure 1. Initial intraoral photographs

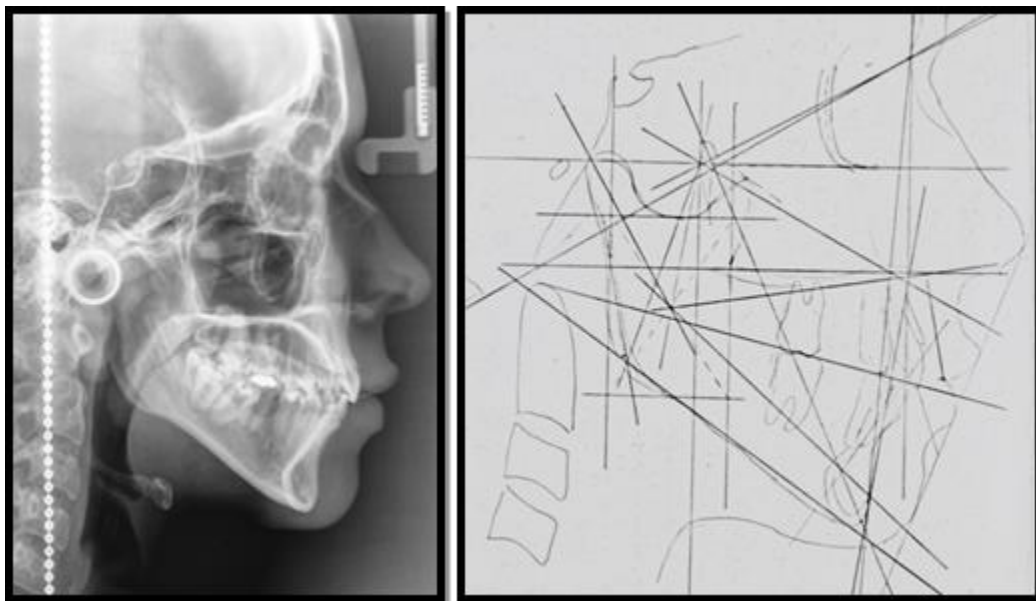


Figure 2. Initial lateral cephalic Rx with Ricketts cephalometric analysis

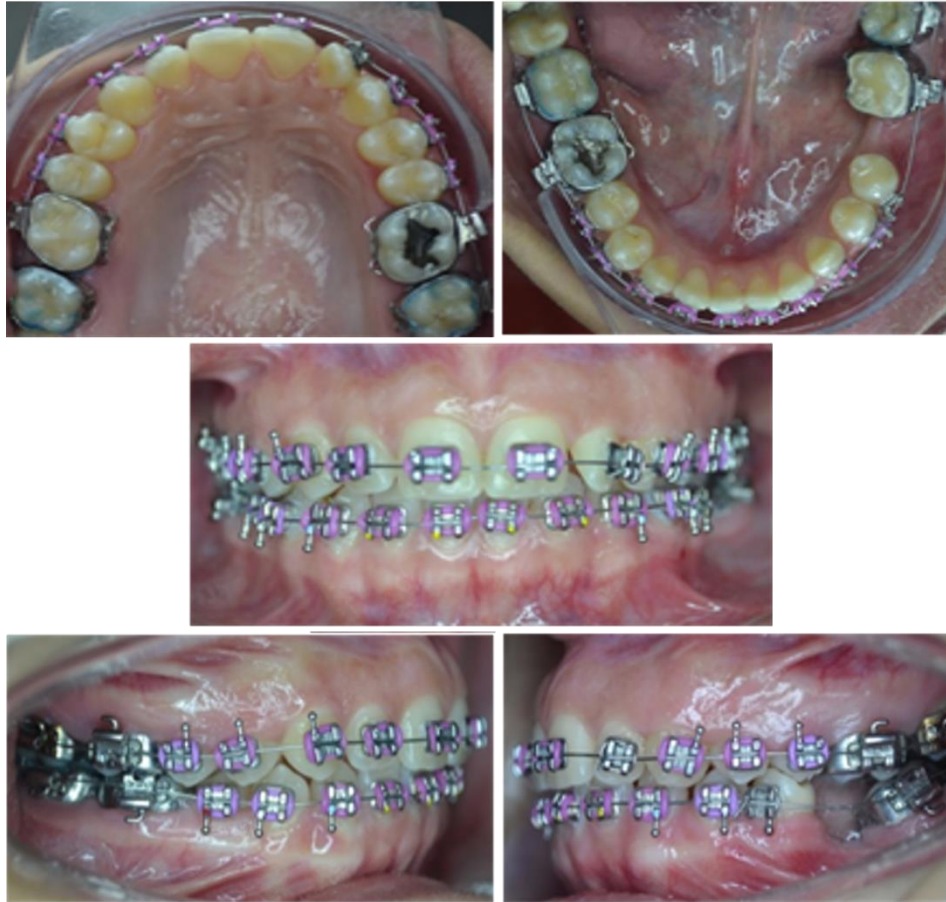

Figure 3. Intraoral photographs. Alignment and leveling, 0.022" Roth fixed orthodontic apparatus

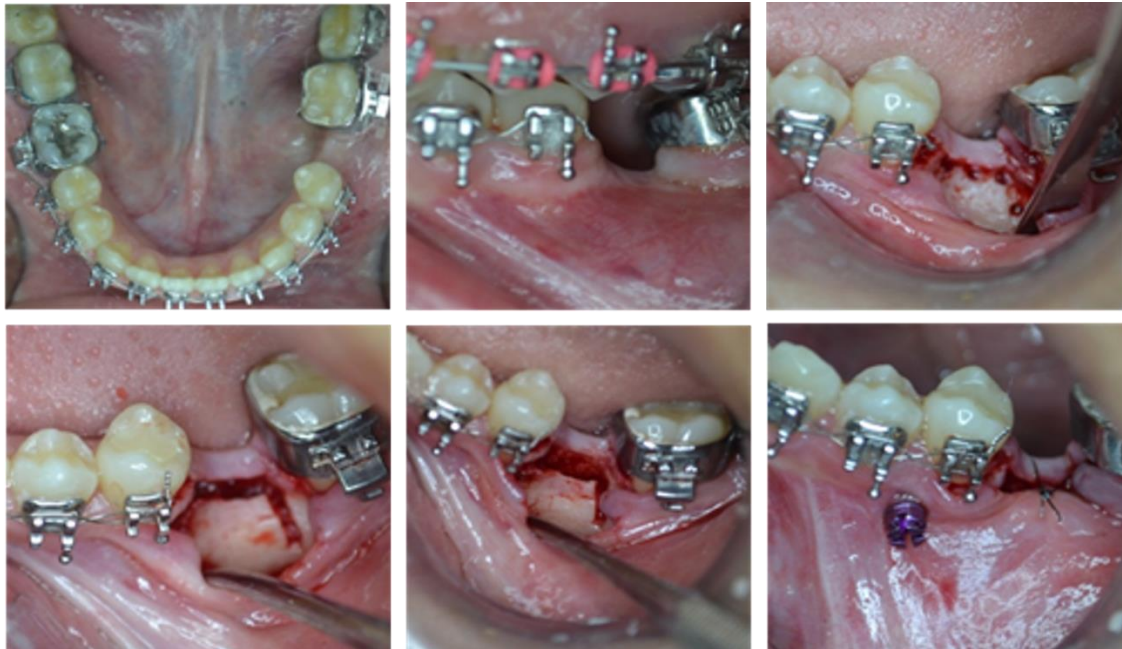

Figure 4. Flexicortotomy

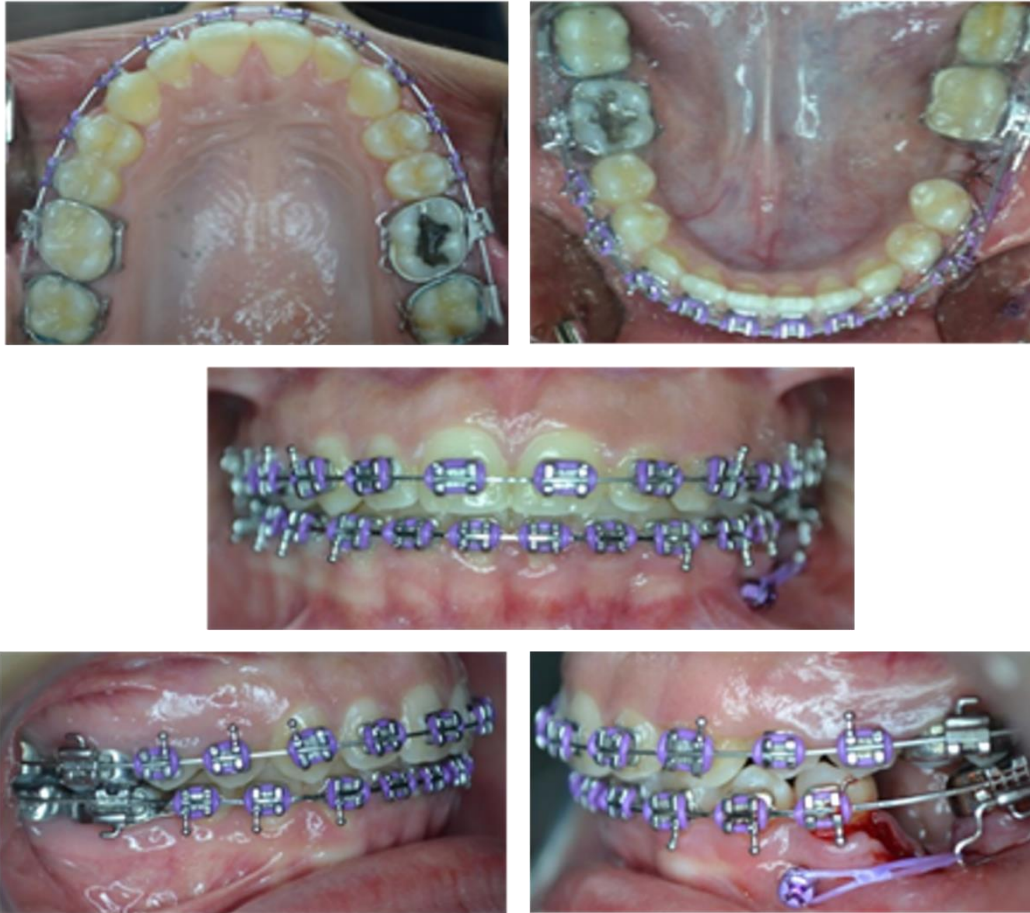

Figure 5. Intraoral photographs, flexicorticotomy, and placement of orthoimplant and power arm

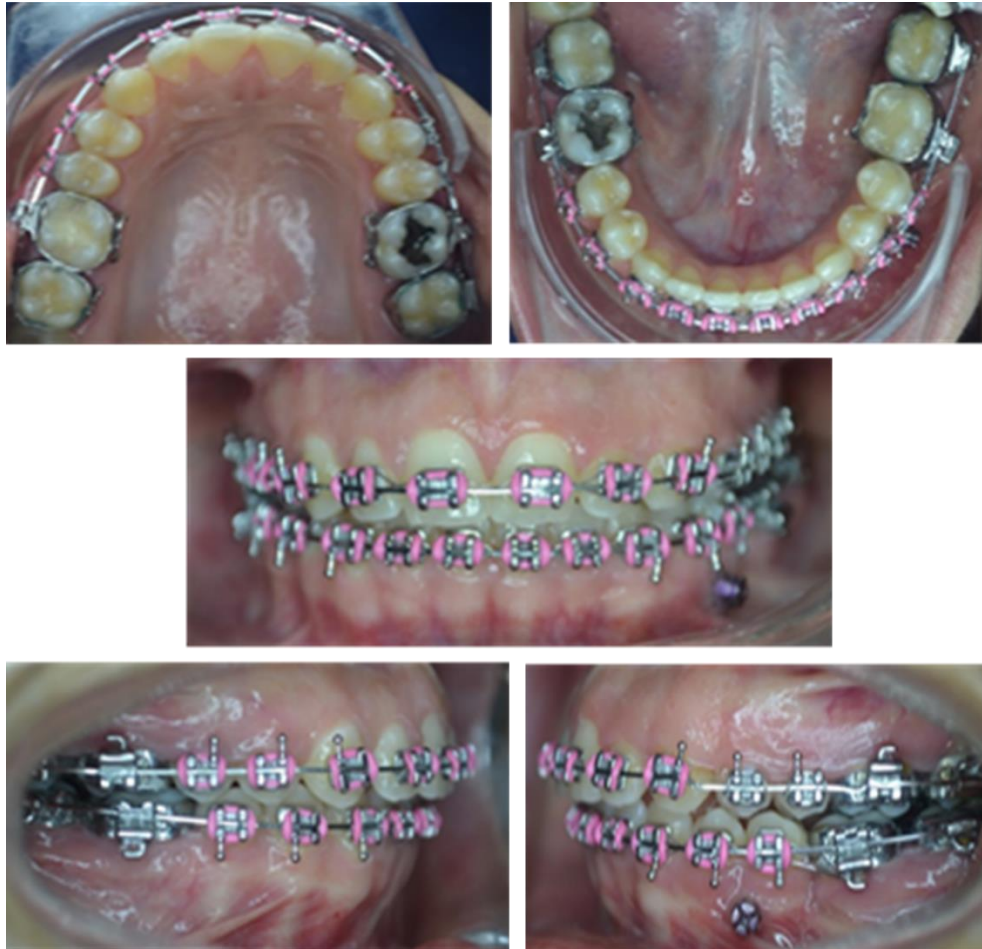

Figure 6. Intraoral photographs. Follow-up 1 year after flexicorticotomy

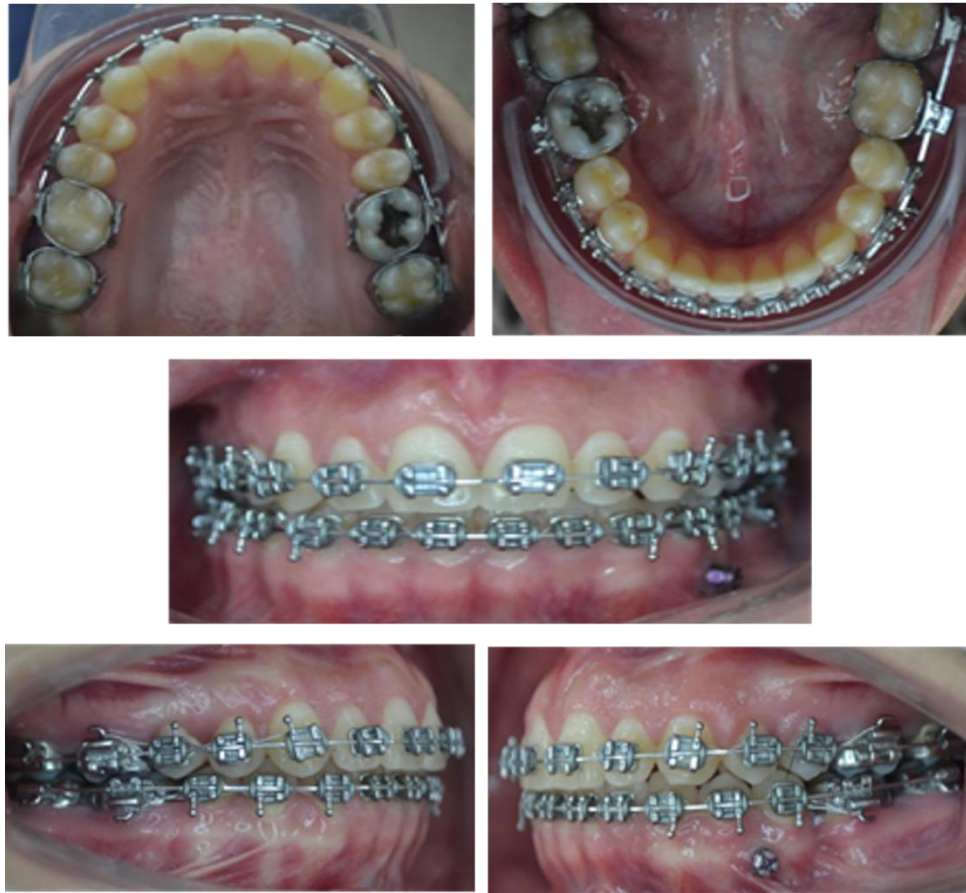

Figure 7. Completion

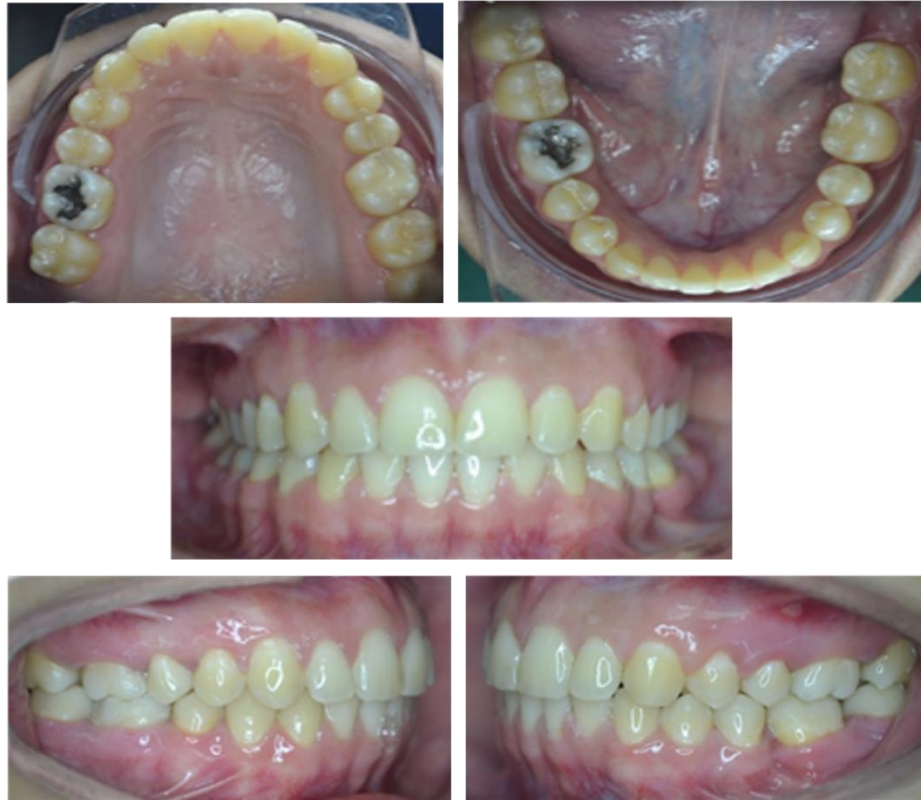

Figure 8. Final intraoral photographs

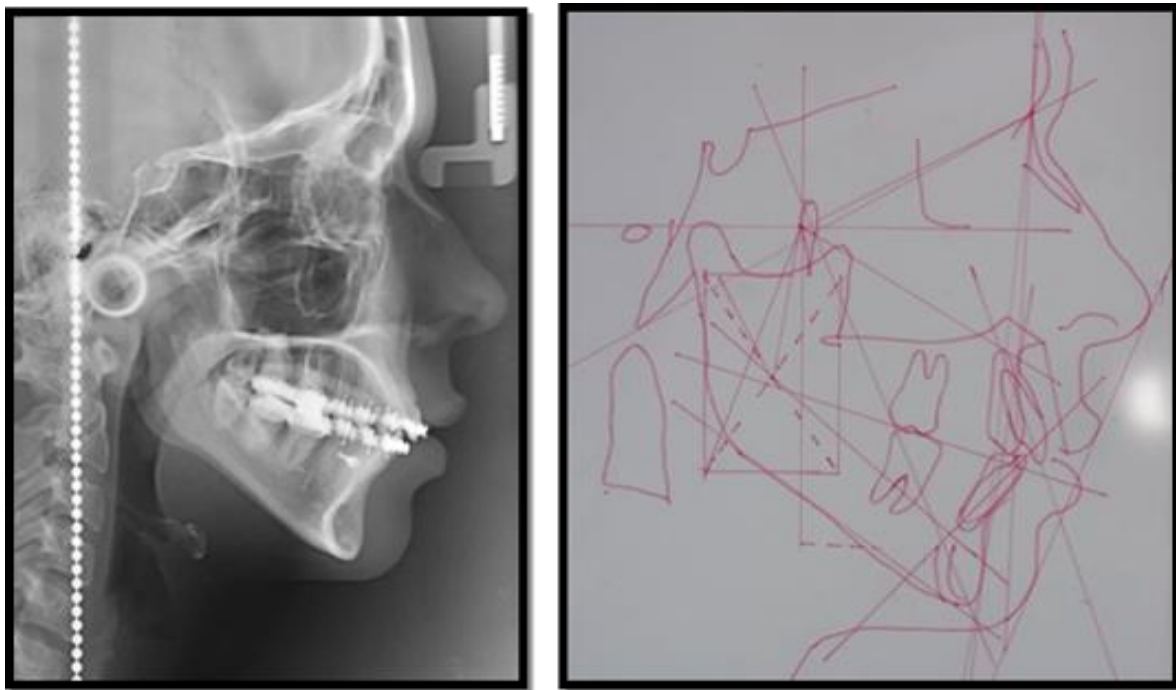


Figure 9. Final lateral cephalic Rx with Ricketts cephalometric analysis




Figure 10. Cephalometric superimposition, showing mesialization of tooth 36. In purple: tooth 36 pre-treatment, in red: tooth 36 post-treatment.