

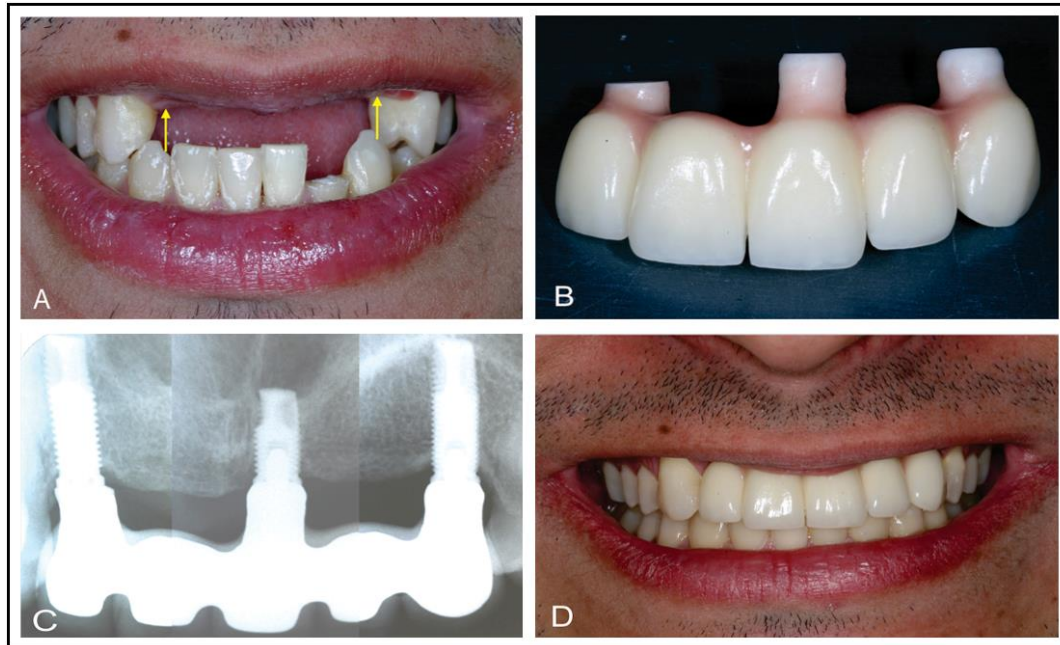Figure 1. Case 1. A. Loss of 5 anterior teeth, partial exposed residual alveolar process, average smile. B. Screw retained fixed partial dental prostheses with pink ceramic papilla simulation. C. Radiographic control. D. Smile showing the pink ceramic papilla simulation.

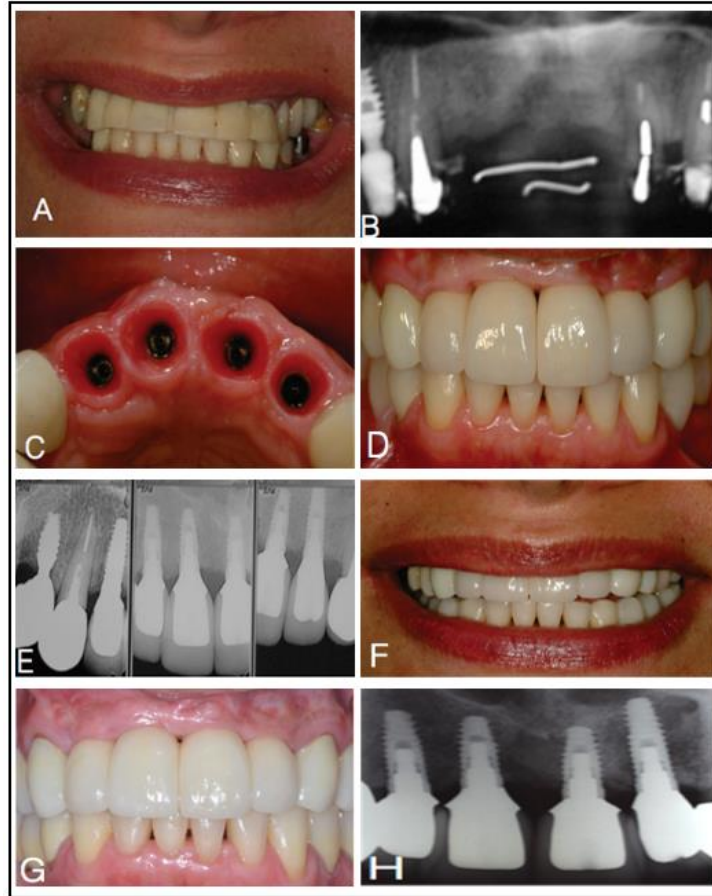


Figure 2. Case 2. A. Low smile line, unaesthetic anterior provisional fixed partial prostheses. B. Initial radiographic control. C. Adequate inter-implant and implant-teeth distance after guide bone and tissue regeneration. D. (MAISR) all ceramic screw-retained crowns. E. Base line radiographic control. F. Final smile. G. Five-year clinical and radiographic follow-up and H

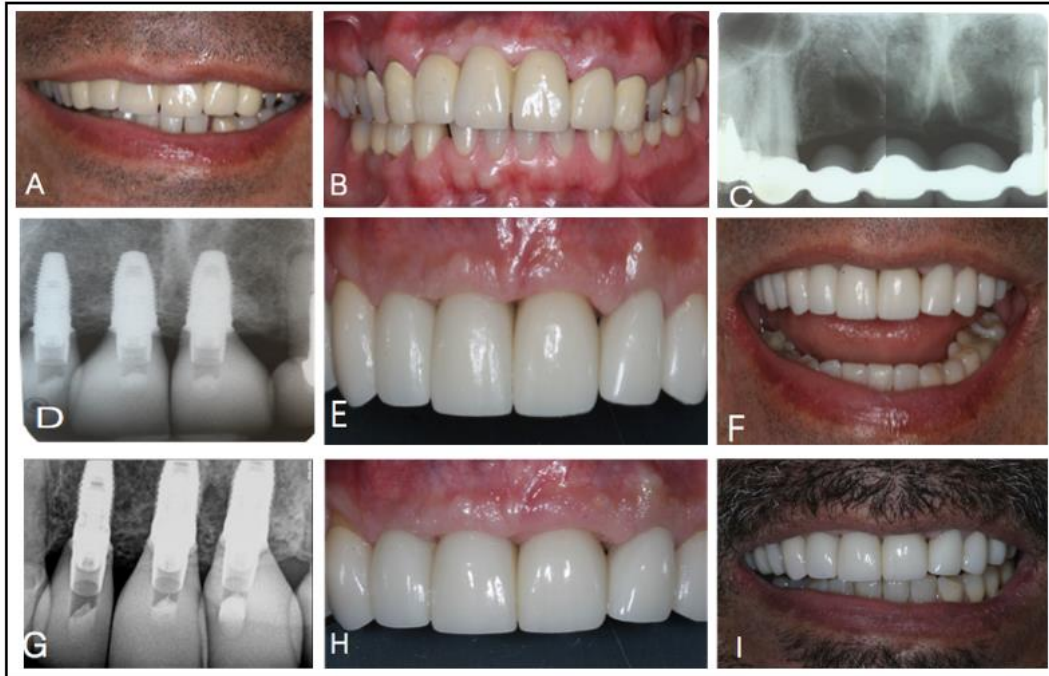


Figure 3. Case 3. A. Low smile line. B. Metal ceramic fixed partial denture. C. Initial periapical radiograph. D. Radiographic control at base line. E. Three adjacent individual implant supported restorations screw-retained metal free ceramic crowns at baseline. F. Smile line at base line. G. Two years follow up H and I.