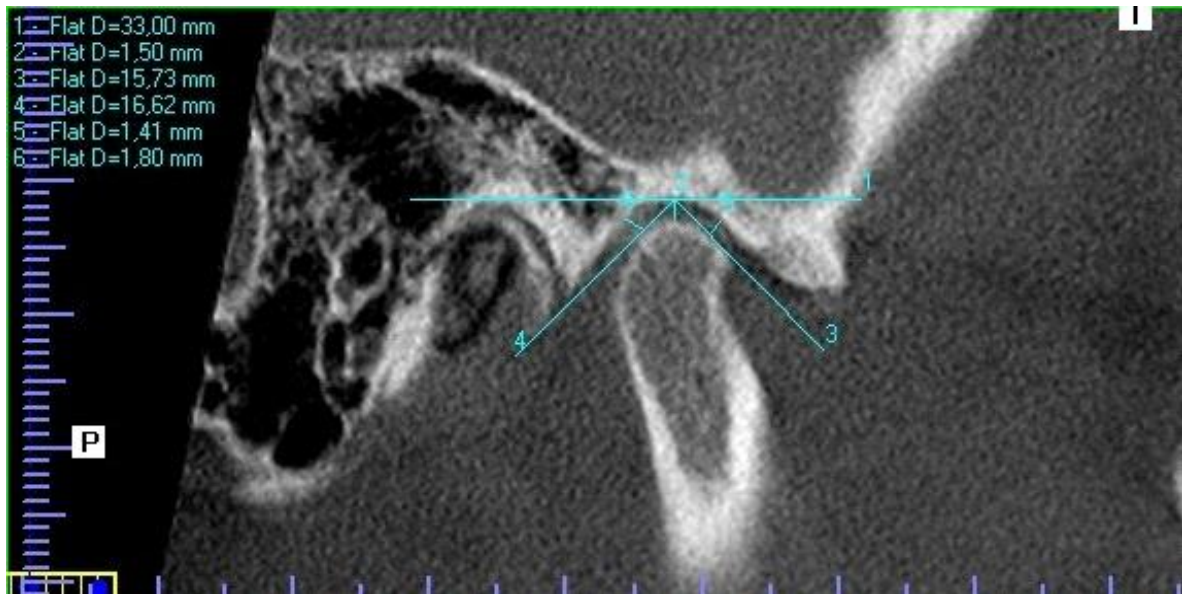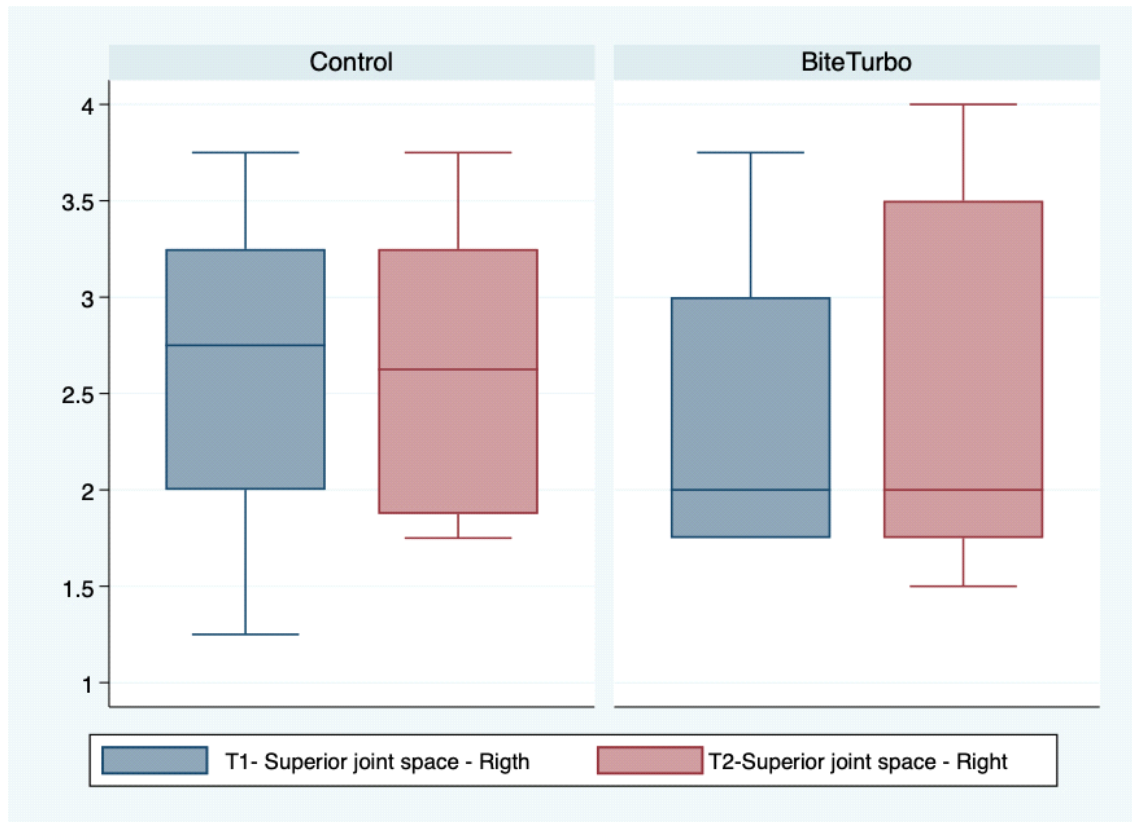


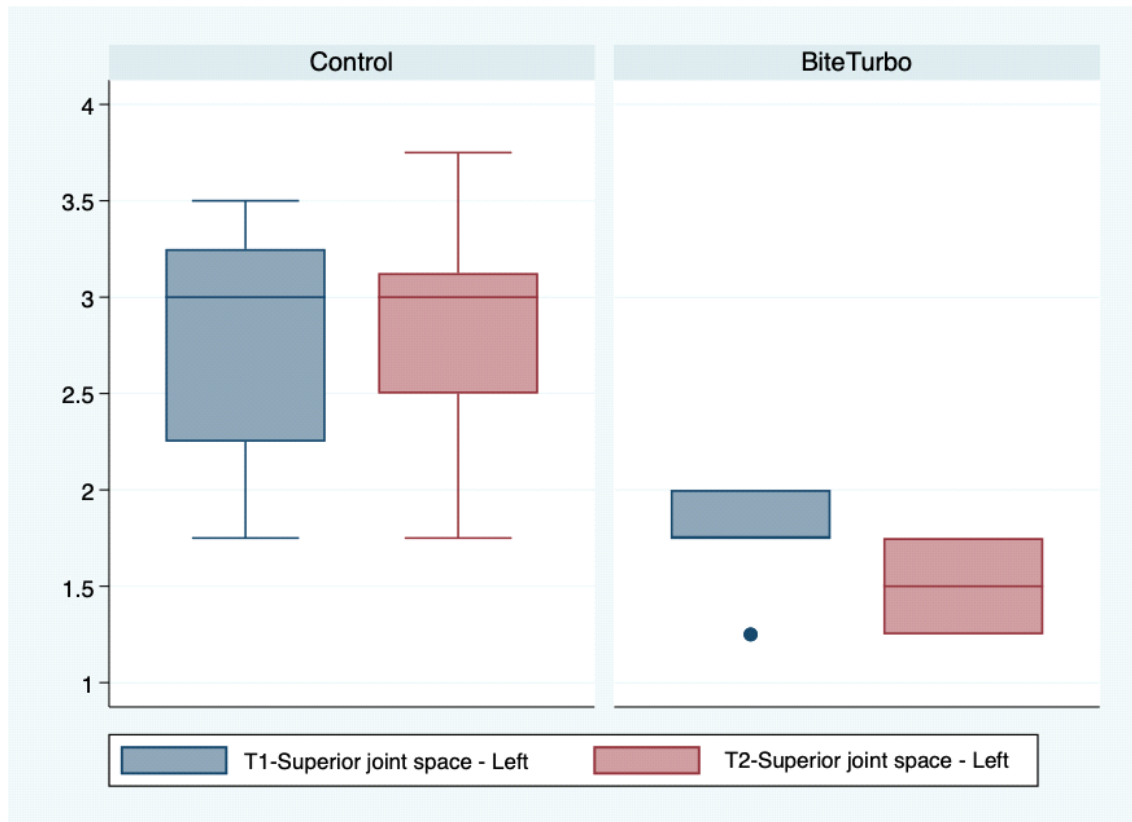
**Figure 1.** A patient's CBCT. The true horizontal line was taken as a reference to establish condyle position in the glenoid fossa. 2 is the upper articular space, 5 is the anterior articular space, 6 is the posterior articular space

Source: by the authors



*Figure 2. Box plot for the right upper articular space at T1 and T2 in both groups*

Source: by the authors



*Figure 3. Box plot for the left upper articular space at T1 and T2 for both groups*

Source: by the authors