

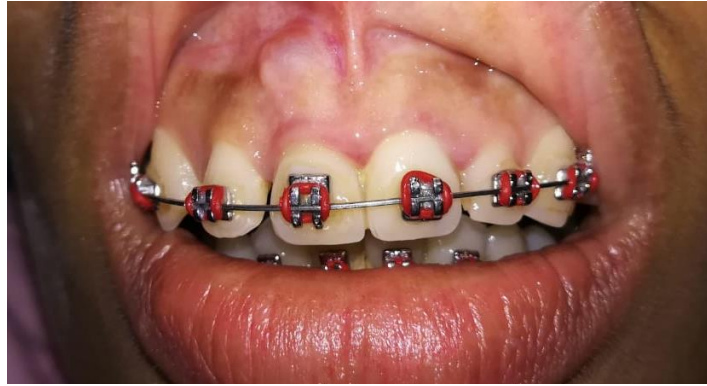

Figure 1. Clinical view of free gingiva lesion on top right quadrant

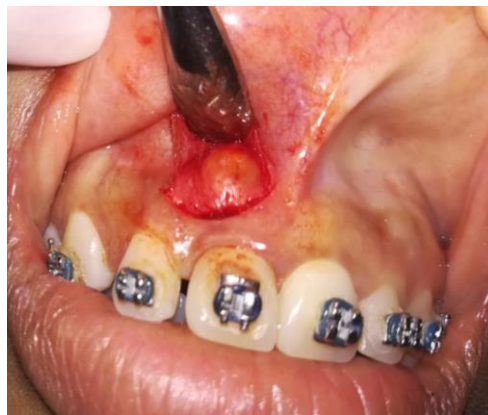

Figure 2. Lesion exposure

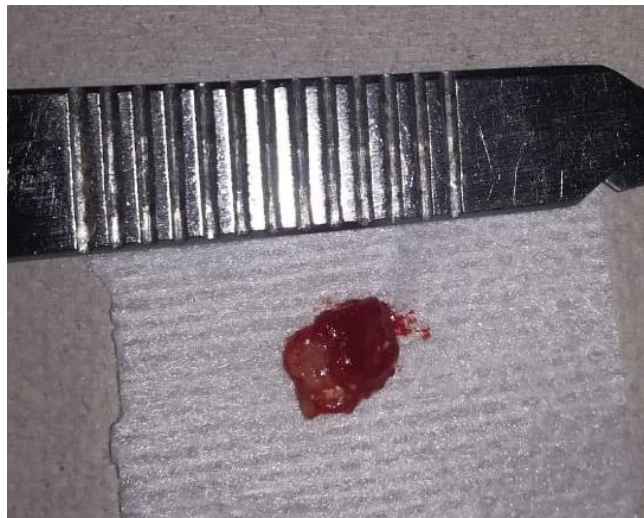

Figure 3. Macroscopic view of the resected specimen

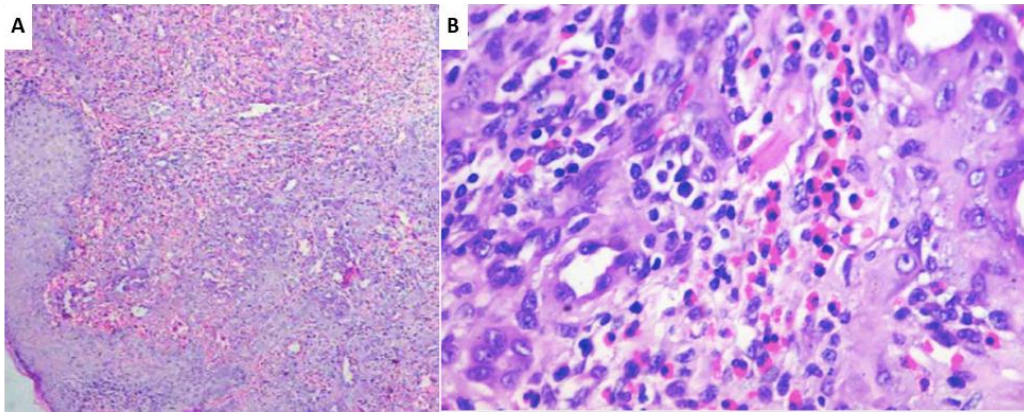


Figure 4. Microphotographs showing the presence of eosinophilia and vascular proliferation. A. 10X. B. 40X