

Tissue fibrosis and its correlation with malignancy in canine mammary tumors[□]

Fibrosis tisular y su correlación con malignidad en neoplasias mamarias caninas

Fibrose tecidual e sua correlação com a malignidade em neoplasias mamárias em cadelas

Gabriela N Toledo¹, MV, PhD; Marcus A R Feliciano^{1, 2*}, MV, PhD; Ricardo A R Uscategui¹, MV, PhD; Geórgia M Magalhães³, MV, PhD, Gabriela M Madruga¹, MV, MSc; Wilter R R Vicente¹, MV, PhD.

¹Faculdade de Ciências Agrárias e Veterinárias, Universidade Estadual Paulista “Júlio de Mesquita Filho” (Unesp) – Jaboticabal, Brazil.

²Universidade Federal do Recôncavo da Bahia (UFRB), Cruz das Almas, Brazil.

³Instituto Federal de Educação, Ciência e Tecnologia do Sul de Minas, Muzambinho, Brazil.

(Received: March 2, 2017; accepted: November 21, 2017)

doi: 10.17533/udea.rccp.v31n4a06

Abstract

Background: Fibrosis is present in several pathologies associated with mammary carcinogenesis. **Objective:** To evaluate and quantify the fibrosis present in malignant and benign mammary neoplasms in bitches. **Methods:** Eighty-three samples were divided according to histopathological diagnosis into benign (n= 21) and malignant (n= 62) neoplasms. Haematoxylin-eosin and Masson’s trichrome were used to locate the connective tissue, and the extent of fibrosis was assessed with image software. **Results:** Benign neoplasms were classified into adenomas (cystic, complex, and tubular), benign mixed tumor, and ductal and lobular hyperplasia. Malignant neoplasms were classified as carcinomas (complex, mixed tumor, *in situ* tubular, tubulopapillary, and solid). Grade I was the most prevalent histopathological class, followed by grade II and III. Fibrosis was classified as severe, moderate, or discrete. No significant (p>0.05) difference was observed for the percentage of fibrosis between malignant and benign group neoplasms. However, difference (p=0.028) was found for fibrosis percentage between histopathological subtypes of tumors. The benign subtype of lobular hyperplasia presented differences between cystic adenoma and benign mixed tumor. The *in situ* malignant tubular carcinoma subtype presented differences between solid and tubulopapillary carcinoma. **Conclusions:** Fibrosis in canine mammary tumors can be estimated with Masson’s trichrome staining.

Keywords: biological biomarkers, breast cancer, dogs, histological stain, histopathology, Masson’s trichrome.

□ To cite this article: Toledo GN, Feliciano MAR, Uscategui RAR, Magalhães GM, Madruga GM, Vicente WRR. Tissue fibrosis and its correlation with malignancy in canine mammary tumors. Rev Colomb Cienc Pecu 2018; 31(4):295-303

* Corresponding author: Marcus Antonio Rossi Feliciano. Faculdade de Ciências Agrárias e Veterinária, Universidade Estadual Paulista “Júlio de Mesquita Filho” (Unesp). Via de Acesso Prof. Paulo Donato Castellane s/n, Jaboticabal, Brazi. CEP: 14884-900, Jaboticabal-SP. Tel.: +55 16 981110504. E-mail: marcusfeliciano@yahoo.com.br

Resumen

Antecedentes: La fibrosis está presente en diversas patologías asociadas con carcinogénesis mamaria. **Objetivo:** Analizar si existe una correlación entre fibrosis tisular y malignidad en tumores mamarios caninos. **Métodos:** 83 muestras de tejido mamario fueron divididas en masas benignas (n=21) y malignas (n=62), de acuerdo con sus características histopatológicas. En estas muestras se utilizaron las coloraciones de hematoxilina-eosina y tricromo de Masson para localizar el tejido conectivo y se analizó la proporción y cuantificación de fibrosis en los mismos con un software de imagen especializado. **Resultados:** Las masas mamarias benignas se diagnosticaron como adenomas (quístico, complejo y tubular), tumor mixto benigno, e hiperplasia ductal y lobular; las masas malignas, como carcinomas (complejo, tumor mixto, tubular *in situ*, túbulopapilar y sólido). Los tumores grado I fueron los más prevalentes, seguidos por los grados II y III. La fibrosis se clasificó como discreta, moderada o severa. No se observó diferencia ($p>0,05$) en el porcentaje de fibrosis entre neoplasias benignas y malignas. No obstante, el porcentaje de fibrosis mostró diferencias ($p=0,028$) entre subtipos tumorales. La hiperplasia lobular fue diferente en relación a los adenomas quísticos y tumor mixto mamario. El subtipo maligno carcinoma tubular *in situ* fue diferente respecto a los carcinomas complejo, mixto maligno, sólido, y túbulopapilar. **Conclusiones:** La fibrosis en los tumores mamarios caninos se puede estimar por la tinción con tricromo de Masson.

Palabras claves: biomarcadores tumorales, cancer de mama, caninos, coloración histológica, histopatología, Masson's trichrome.

Resumo

Antecedentes: A fibrose participa em diversas patologias e ainda possui função adicional associada à carcinogênese mamária. **Objetivo:** Objetivou-se avaliar a fibrose e correlacionar com a malignidade nas neoplasias mamárias em cadelas. **Métodos:** 83 amostras foram divididas em dois grupos baseado no diagnóstico histopatológico: neoplasias benignas (n= 21) e neoplasias malignas (n= 62). Hematoxilina e eosina e Tricômico de Masson foram usadas para visualização de tecido conjuntivo e avaliação de fibrose através de programa de imagens. **Resultados:** As neoplasias benignas foram: adenoma (cístico, complexo e tubular), tumor misto benigno, hiperplasia ductal e lobular. As malignas foram: carcinoma complexo, em tumor misto maligno, tubular *in situ*, túbulopapilar e sólido. O grau histopatológico prevalente foi grau I, seguido do grau II e III. A fibrose nas neoplasias mamárias malignas foi classificada como severa, moderada e discreta. Não houve diferença significativa ($p>0,05$) na porcentagem de fibrose entre neoplasias malignas e benignas. A estatística revelou diferença significativa ($p=0,028$) na porcentagem de fibrose em relação ao diagnóstico histopatológico. O subtipo benigno hiperplasia lobular apresentou diferença entre o adenoma cístico e o tumor misto benigno. O subtipo maligno carcinoma tubular *in situ* apresentou diferença entre carcinoma complexo, misto maligno, sólido e túbulopapilar. **Conclusões:** A fibrose nos tumores mamários caninos pode ser estimada através da coloração de tricrômio de Masson.

Palavras-chaves: biomarcadores tumorais, cães, câncer de mama, coloração histológica, histopatologia, Tricômico de Masson.

Introduction

Fibrosis is an active biosynthetic process characterized by unregulated accumulation of extracellular matrix (ECM) in chronic ischemic lesions as a result of chemical or toxic agents, viral and non-viral infections, physical damage, and immunological reactions. Tumor stiffness is a feature associated with the tumoral microenvironment and recent studies have indicated that it may influence neoplastic progression involving ECM (Thannickal, 2004; Wynn, 2008; Guarino *et al.*, 2009).

Tissue stiffness is clinically considered an oncogenic risk factor when correlated to other conditions, as seen in dense mammary tissue and liver cirrhosis. In humans, tumor stiffness is one of the clinical features examined during palpation of the mammary gland (Liu *et al.*, 2016) as the neoplastic tissue is stiffer than normal breast tissue and the stiffening process begins at the early stages of tumoral development (Barr *et al.*, 2015). Chronic fibrosis and inflammation has been associated with mammary tumors, indicating poor prognosis for the patients (Kalliuri and Zeisberg, 2006; Carvalho *et*

al., 2016). Studies have demonstrated that as fibrosis progresses, the signaling of pre-neoplastic cells with pro-inflammatory cytokines gradually increases (Kalliuri and Zeisberg, 2006).

Mammary tumors are the most common neoplasms in entire bitches and approximately 40 to 50% are considered malignant (Soremo, 2003; Cassalli *et al.*, 2014; Visan *et al.*, 2016). Thus, canine mammary tumors can be used as a relevant animal model for breast cancer studies in women (Klopfleisch *et al.*, 2011; Queiroga *et al.*, 2011; Feliciano *et al.*, 2012; Jensen-Jarolim *et al.* 2015; Visan *et al.*, 2016; Carvalho *et al.*, 2016). In spite of this, the correlation between mammary tumors and the degree of fibrosis in bitches has yet to be evaluated.

Therefore, it is hypothesized that canine malignant mammary tumors with high histopathological grade and short evolution period have more fibrosis than benign tumors. Thus, the aim of this study was to evaluate and quantify fibrosis present in malignant and benign mammary neoplasms in bitches.

Materials and methods

Ethical considerations

The methods used were in agreement with the Ethics Committee on the Use of Animals (CEUA, process N. 023705/12) of UNESP.

Type of study, location, animals and samples

A retrospective study was conducted using mammary tumor samples from animals admitted to the Serviço de Obstetrícia Veterinária da Faculdade de Ciências Agrárias e Veterinárias, Universidade Estadual Paulista (UNESP), Jaboticabal Campus, Brazil, from January 2013 to February 2014.

Eighty-three samples of mammary tumors from bitches of different ages and breeds were used in this study. One sample was selected per animal. In animals that presented two or more histological types, only the sample from the most histologically aggressive type was selected.

At the time of patient admittance, the tumors were examined and tumoral nodule diameter measured using a pachymeter (Lee Tools, Santo André, SP, Brazil). Nodule diameter was classified (T) according to the World Health Organization (Owen, 1980) into T1 (≤ 3 cm), T2 (between 3 and 5 cm), and T3 (≥ 5 cm). Nodule size, animal age, and evolution time of tumor were tested for correlation with degree of tumoral fibrosis. Following mastectomy, fragments of mammary tumors were collected and processed for histopathological diagnosis under light microscopy. Samples were fixed in 10% phosphate buffered formalin (pH 7.4) for 24 hours, dehydrated in decreasing alcohol solutions, diaphonized in xylene, and embedded in paraffin. Sections (5 μ m) were stained with haematoxylin-eosin (HE) for further identification of main morphological alterations.

Neoplasms were classified under light microscopy, according to criteria by Misdorp *et al.* (1999). Histopathological grading was performed according to the methodology by Elston and Ellis (1998), and the samples distributed into two experimental groups: Group 1 (G1, benign neoplasms, n= 21) and Group 2 (G2, malignant neoplasms, n= 62).

Histopathological sections stained with Masson's trichrome (MT) were used to view connective tissue and determine fibrosis degree. A score was generated according to the extent of fibrosis in the samples. Fibrosis degree was determined by the Banff Classification (Solez *et al.*, 1993), as follows: Grade 1 (discrete, 6 - 25% of the sample), Grade 2 (moderate, 25.01 - 50% of the sample), and Grade 3 (severe, $\geq 50.01\%$ of the sample).

To evaluate the extent of fibrosis, five fields from each slide were randomly photographed (20x objective) and analyzed using the Image-Pro Plus16, version 4.5 (Medica Cybernetics, Inc., Rockville, MD, USA) processing software, which automatically calculates the percentage of staining in the areas marked in the field. The results for each slide were obtained by calculating the mean percent of the areas marked in the five fields (Figure 1).

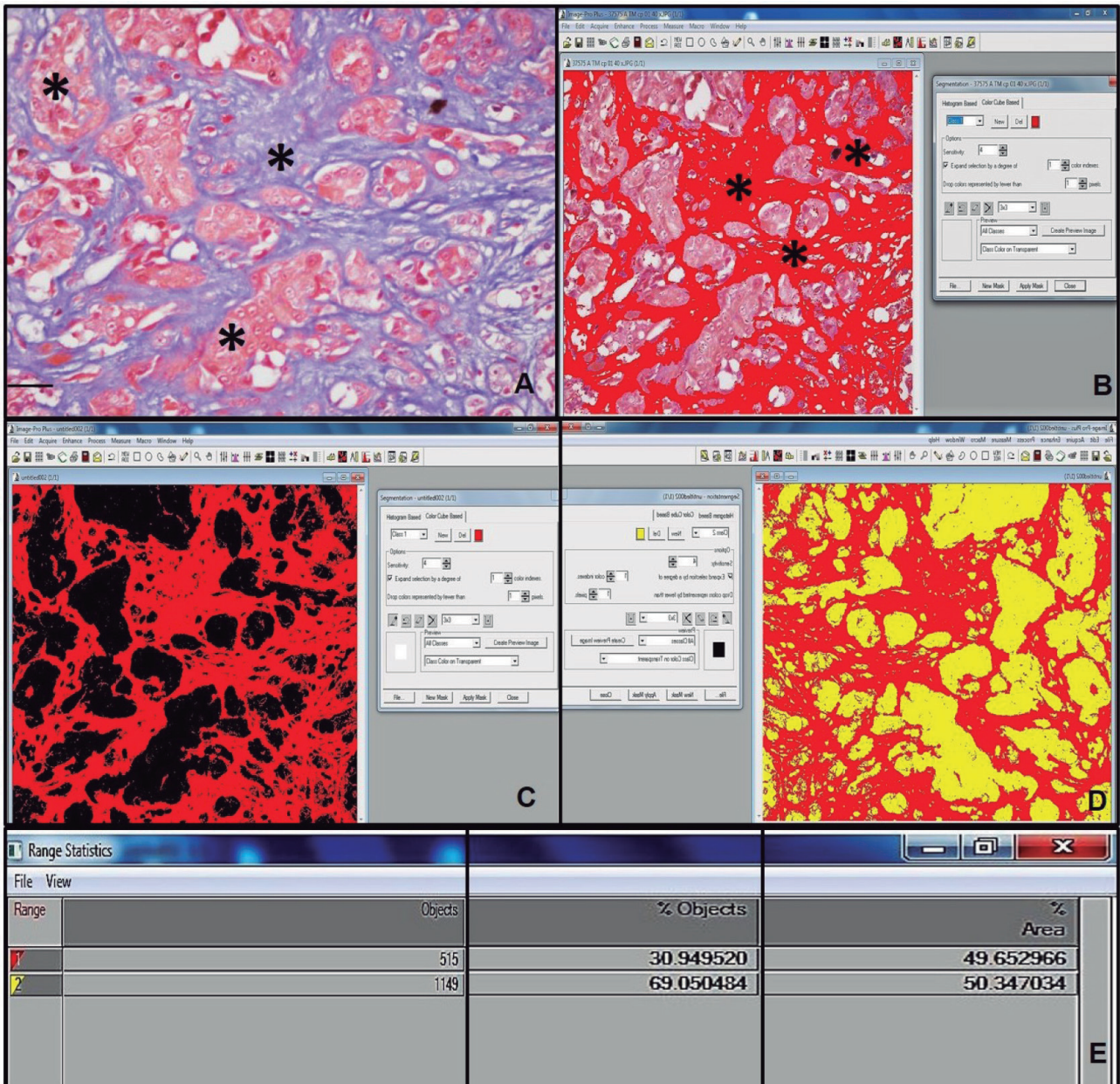


Figure 1. Histopathological photomicrograph of the mammary gland in a bitch. A: Solid carcinoma (*), Masson’s trichrome (MT), bar=100 µm. B: Histopathological photograph preparation of the mammary gland of a bitch through Image-Pro Plus16 software. Fibrosis area marked by Image-Pro Plus 16 image software (*). C: Marked fibrosis area analysis (red), chosen automatically by the image program. D: Calculation of marked fibrosis area (red) and background color (yellow). E: Result of automatic calculation of fibrosis area in solid carcinoma.

Statistical analysis

The percentage of fibrosis was compared between benign and malignant neoplasms regarding histopathological diagnosis, age of the animal, tumor evolution time, and histopathological grade

using the non-parametric Kruskal-Wallis test. The correlation between histopathological grade, age, tumor evolution time, and malignancy was performed by Pearson’s test. Once the median of the fibrosis percentage in malignant neoplasms was calculated, the sensitivity, specificity, positive predictive value

(PPV), negative predictive value (NPV), and accuracy of the diagnostic test for malignancy were determined. The relationship between fibrosis percentage and probability of the diagnosis being malignant was also tested by binary logistic regression. Differences were considered significant at $p < 0.05$.

Results

Out of the eighty-three samples used in this study, 21 (25.30%) were classified as benign and 62 (74.70%) as malignant neoplasms. The benign tumors were further classified into cystic adenomas (1, 1.20%), complex adenoma (4, 4.81%), tubular adenoma (2, 2.40%), benign mixed tumor (4, 4.81%), ductal hyperplasia (4, 4.81%), and lobular hyperplasia (6, 7.22%). The malignant neoplasms were classified into complex carcinoma (7, 8.43%), malignant mixed tumor (21, 25.30%), *in situ* tubular carcinoma (3, 3.61%), tubulopapillary carcinoma (18, 21.68%), and solid carcinoma (13, 15.66%) (Figure 2). Grade I was the most prevalent histopathological grade in malignant neoplasms (27, 43.55%), followed by grade II (25, 40.32%) and III (10, 16.13%).

Image analysis of the fibrotic tissue area in 45 samples revealed prevalence of severe fibrosis in malignant mammary neoplasms, followed by a lower occurrence of moderate and discrete fibrosis. Moderate fibrosis was also prevalent in benign mammary tumors, followed by severe and discrete fibrosis (Table 1). Fibrosis degree was classified as discrete, moderate or severe. When evaluating fibrosis intensity in canine breast neoplasms (discrete, moderate or severe) between the experimental groups, no statistical difference was found ($p = 0.174$). Mean value (\pm SD) in group 1 was 3.0 ± 1.0 , and group 2 was 2.5 ± 1.0 .

Table 1. Frequency and percentage (%) of fibrosis degrees in benign and malignant mammary tumors in bitches.

Malignant Degree of Fibrosis	Frequency	%	Benign Degree of Fibrosis	Frequency	%
Discrete	05	6.02	Discrete	01	1.20
Moderate	12	14.46	Moderate	12	14.46
Severe	45	54.22	Severe	08	9.64
Total	62	74.70		21	25.30

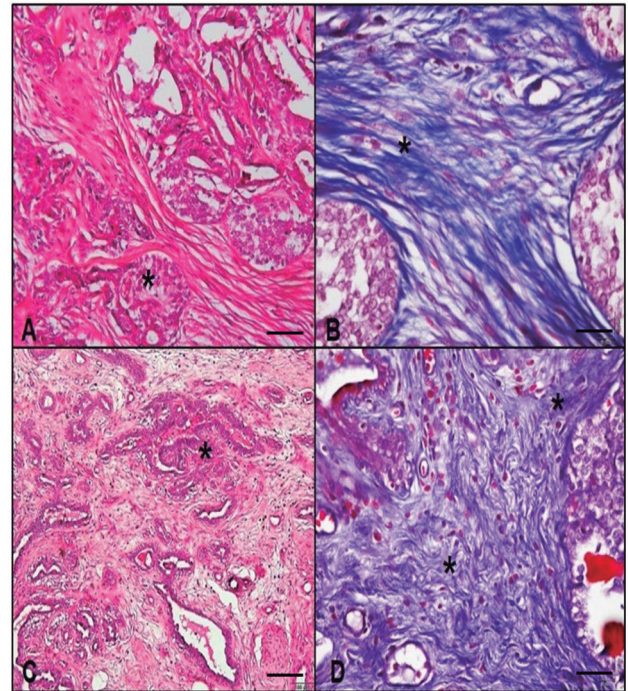


Figure 2. Histopathological photomicrograph of the mammary gland in a bitch. A: Malignant mixed tumor (*), HE, bar 100 μ m. B: Area of fibrosis in malignant mixed tumor (*), MT, 100 μ m bar. C: Complex carcinoma (*), HE, bar 100 μ m. D: Area of fibrosis in complex carcinoma (*), MT, bar 100 μ m. MT: Masson's trichrome, HE: haematoxylin-eosin.

No significant ($p = 0.134$) difference in the percentage of fibrosis between malignant and benign tumors was observed. Mean (\pm SD) percentage of fibrosis in malignant and benign neoplasms was 58.2 ± 24.50 and 49.9 ± 19.10 , respectively.

Fibrosis percentage was positively correlated with histopathological grade of tumors ($p = 0.035$, $r = 0.23$), which in turn had a positive correlation with age ($p = 0.003$, $r = 0.32$). In malignant tumors, severe fibrosis ($\geq 50.01\%$ of the sample) was present, in decreasing order, in samples of *in situ* tubular carcinoma, malignant mixed tumor, solid carcinoma, complex carcinoma, and tubulopapillary carcinoma. Solid carcinoma, complex carcinoma, and tubulopapillary carcinoma presented discrete fibrosis ($\leq 25\%$ of the sample). The benign histological types with severe fibrosis were mixed tumor, cystic adenoma, and ductal hyperplasia. Tubular adenoma, complex adenoma, and lobular hyperplasia presented moderate fibrosis (25.01 - 50% of the sample) and

complex adenoma showed discrete fibrosis ($\leq 25\%$ of the sample).

Fibrosis percentage was different ($p=0.0284$) between histopathological subtypes, as shown in Table 2.

Table 2. Median \pm interquartile range (IQR) of tissue fibrosis (%) in the different histopathological subtypes of benign and malignant canine mammary tumors.

Groups	Median \pm IQR
Group I – Benign	
Cystic Adenoma	56.30 \pm 0 ^{ab}
Complex Adenoma	56.55 \pm 0.00 ^{ab}
Tubular Adenoma	42.45 \pm 2.09 ^b
Ductal Hyperplasia	57.75 \pm 6.95 ^{ab}
Lobular Hyperplasia	39.35 \pm 13.10 ^a
Benign Mixed Tumor	63.60 \pm 4.30 ^{ab}
Group II – Malignant	
Complex Carcinoma	47.70 \pm 19.15 ^{ab}
Malignant Mixed Tumor	63.45 \pm 15.00 ^{ab}
<i>In situ</i> Tubular Carcinoma	73.30 \pm 3.90 ^a
Solid Carcinoma	61.75 \pm 10.45 ^{ab}
Tubulopapillary Carcinoma	51.10 \pm 16.80 ^a

Different superscript letters (^{a, b}) within the same column indicate significant difference between histological types ($p < 0.05$) by the Dunns' test. IQR: \pm interquartile range.

Regarding tumoral evolution time, the nodules appeared between one and 36 months. Mean evolution time in benign and malignant neoplasms was 7.76 and 7.06 months, respectively. There was no significant difference in the percentage of fibrosis between different evolution times ($p=0.14$). Furthermore, fibrosis percentage was negatively correlated with tumoral evolution time ($p=0.008$, $r=-0.3$), suggesting that evolution time does not determine the chronicity of the process.

As the median percentage of fibrosis in malignant neoplasms was 58%, the sensitivity and specificity of the test to estimate tumor malignancy were evaluated. The test showed 75% prevalence, 45% sensitivity, 86% specificity, 90% positive predictive value (PPV), and 34% negative predictive value (NPV). The positive and negative verisimilitude were 94 and 24%, respectively. Test accuracy was 38%.

There was no significant ($p=0.528$) difference in the percentage of fibrosis between the different nodule

sizes, with mean (\pm SD) percentage of 54.93 ± 21.68 , 57.51 ± 22.69 , and 60.36 ± 31.63 for T1, T2, and T3 masses, respectively. There was no positive correlation between tumoral size and fibrosis percentage, animal age, histopathological grade, or tumoral evolution time, when they were compared separately.

Binary logistic regression was used to test the relationship between fibrosis percentage and probability of a malignant diagnosis. Fibrosis percentage was predictive of malignancy in only 46% of the tumor samples ($p=0.074$).

Discussion

Histopathological analysis in the present study revealed that malignant neoplasms corresponded to 74.70% of the samples, in agreement with Oliveira *et al* (2003). Our findings also agreed with Oliveira Filho *et al* (2010), Sorenmo *et al* (2009), Feliciano *et al* (2012), and Soler *et al* (2016), who reported similar findings (73.4, 79.9, 60, and 65.38%; respectively). The frequency of benign and malignant neoplasms reported in the literature varies markedly due to different classification methods of mammary tumors and lack of standard criteria to differentiate tumor types (Cassali *et al.*, 2003). In other countries, the percentages of malignant neoplasms reported are often lower than 54% (Itoh *et al.*, 2005; Sorenmo *et al.*, 2009; Lana *et al.*, 2013; Goldshimit *et al.*, 2017). On the other hand, some studies in Brazil have reported the prevalence of malignant neoplasms ranging from 60 to 91% (Nardi *et al.*, 2002; Oliveira *et al.*, 2003; Feliciano *et al.*, 2012). This difference is probably due to the high prevalence of malignant neoplasms in Brazilian studies and the extensive time elapsed from tumor appearance to clinical evaluation (Oliveira *et al.*, 2003). Furthermore, there is evidence that prolonged evolution time enables progression of benign into malignant tumors (Sorenmo *et al.*, 2009).

A high prevalence of malignant mixed tumor and tubulopapillary carcinoma amongst malignant mammary neoplasms was observed, in agreement with Cintra *et al.* (2014) who reported prevalence of malignant mixed tumor when using Moulton's (1990) classification. However, Soler *et al.* (2016), using the classification by Goldshimidt *et al.* (2011),

reported higher incidence of complex and simple carcinoma in mammary tumors. In the classification by Cassali *et al.* (2011), there were some differences to the classification of malignant mixed tumors. This histological subtype (malignant mixed tumor) is separated from the mixed tumor carcinoma subtype due to its reduced invasiveness and better prognosis.

According to McPhail and Robinson (2010), presence of fibrosis in tumor tissue is considered a histological feature associated with poor prognosis in mammary neoplasms. Although there are other histopathological markers for malignant tumors, it has been suggested that the presence of fibrosis in carcinomas could be used as a prognostic factor in mammary tumors, as it originates from the overreaction of the tumoral stroma, which is comprised mainly of fibroblasts and collagen.

A positive correlation has been reported between fibrosis and mammary tumors in rats when using Picrosirius Red stain, which suggests that neoplasms induced by NMU (N-Methyl-N-Nitrosurea) also have high amount of fibrosis, reinforcing the clinical relevance of fibrosis (McPhail and Robinson, 2010). Furthermore, it has been shown that invasive ductal mammary carcinomas containing fibrosis are more aggressive than those without fibrosis (Hasebe *et al.*, 1996).

In agreement with Soler *et al.* (2016), there were fewer benign tumor samples in the present study than malignant ones, which might explain the lack of significant difference in the parameters between the two types of tumors. Heterogeneity of canine mammary tumors and the limited number of samples make data interpretation challenging; larger samples could result in more significant results. Nevertheless, a positive correlation was observed between histological grade and fibrosis percentage in the tumoral mass, corroborating with the findings by McPhail and Robinson (2010) in rats.

Histologically, fibroblasts and collagen fibers within a fibrotic area are arranged in irregular patterns, associated with increased cellularity and/or fibroblast collagenization. It is still unclear how this dense tissue architecture affects the tumor; however, non-invasive imaging techniques can evaluate collagen *in vivo* and

could identify and delineate a fibrotic focus within the mammary tumor (Brown *et al.*, 2003).

Invasive carcinomas with fibrotic foci are more aggressive than those without fibrosis. Fibrosis has been associated with large tumoral size, great histopathological grade, high proliferative activity of tumoral cells, and necrosis. Smaller studies have shown the independent prognostic significance of fibrosis in patients with invasive breast cancer. Furthermore, it has been shown that the relationship between fibrosis and tumor size could be an important prognostic factor (Van den Eyden *et al.*, 2007).

Thus, it has been demonstrated that presence of fibrosis indicates differences in the malignancy of invasive carcinomas and other mammary tumors (Hasebe *et al.*, 2000). Fibrosis is part of the tumor stroma, indicating that the malignant potential of neoplasms depends not only on the biological features of tumoral cells, but also on the tumoral stroma. Fibrosis consists of fibroblasts or collagen fibers mixed with microvessels and the interaction of these components influences the progression of mammary carcinomas with fibrosis (Hasebe *et al.*, 2000). The presence of atypical fibroblasts in the tumoral stroma, especially in the fibrotic foci, is significantly associated with tumor recurrence and death of patients with invasive ductal mammary carcinoma (Ahn *et al.*, 2012).

The influence of an overactive stroma on neoplastic cells, and vice versa, is still unclear. The way in which *in situ* carcinomas remain localized within the basement membrane or become invasive is not fully understood (Hanahan and Weinberg, 2000; Kalliuri, 2003). Furthermore, stromal fibroblasts secrete metalloproteinase (MMPs) and other cytokines that are important factors in tumor progression (Hasebe *et al.*, 2000). Therefore, it is presumed that the biological factors of the usual fibroblasts are markedly different from those in the fibrotic focus. This indicates heterogeneity in fibroblast characteristics associated with tumoral stroma, as well as neoplastic cells, which may affect patients with mammary carcinomas.

A study using 140 cases of invasive carcinomas in women was performed to determine the prognostic significance of foci of fibrosis (Hasebe *et al.*, 2000),

which was evaluated by the following histological parameters: age, histopathological grade, nodular state (absent or present), size, tumor necrosis (present or absent), and adjuvant chemotherapy (none or administered). The overall disease-free survival time was significantly lower in cases with fibrosis, confirming that its presence and extent are useful histological and prognostic parameters in patients with invasive lobular carcinoma as well as invasive ductal carcinomas (Hasebe *et al.*, 2000).

Several techniques and different histopathological and molecular markers are currently available to evaluate aggressiveness, biological behavior, and prognosis of mammary neoplasms in bitches. Most markers reflect specific aspects of neoplastic cell biology; however, oncogenesis is determined by complex interactions between epithelial and stromal tumor cells. Markers that reflect the behavior of these cells are scarce in Veterinary Medicine; therefore, in the present study, easy and reproducible evaluation of fibrotic areas was proposed as a practical histopathological marker for tumoral aggressiveness.

This study provides evidence that Masson's trichrome staining could be used for assessing fibrosis in canine mammary tumors. Further *in vivo* and *in vitro* studies are necessary to elucidate the complex pathophysiological development of fibrosis in canine mammary tumors, as well as its impact on the interactions between the immune system and chronic diseases. The number of samples used could have limited the evaluation of the correlation between fibrosis and malignancy; therefore, further studies involving a greater number of samples, different breeds, age, groups, malignant and benign histological types, and different histological staining techniques are needed.

Acknowledgments

The authors would like to thank the State of Sao Paulo Research Foundation (FAPESP) for the financial support provided (process number: 2012/16635-2).

Conflicts of interest

The authors declare they have no conflicts of interest with regard to the work presented in this report.

References

- Ahn S, Cho J, Sung J, Lee JE, Nam SJ, Kim KM, Cho EY. The prognostic significance of tumor-associated stroma in invasive breast carcinoma. *Tumor Biol* 2012; 33:1573-1580.
- Barr RG, Nakashima K, Amy D, Cosgrove D, Farrokh A, Schaffer F, Bamber JC, Castera L, Choi BI, Chou YH, Dietrich CF, Ding H, Ferraioli G, Filice C, Friedrich-Rust M, Hall TJ, Nightingale KR, Palmeri ML, Shiina T, Suzuki S, Sporea I, Wilson S, Kudo M. WFUMB guidelines and recommendations for clinical use of ultrasound elastography: Part 2: breast. *Ultrasound Med Biol* 2015; 41:1148-1160.
- Brown E, Mckee T, Ditomaso E. Dynamic imaging of collagen and its modulation in tumors *in vivo* using second-harmonic generation. *Nature Med* 2003; 9:796-800.
- Carvalho MI, Carvalho RS, Pires i, Prada J, Bianchini R, Jensen-Jarolim E, Queiroga FL. A Comparative Approach of Tumor-Associated Inflammation in Mammary Cancer between Humans and Dogs. *BioMed Res Int* 2016. 4917387.
- Cassali GD, Lavallo GE, Nardi AB de, Ferreira E, Bertagnolli AC, Estrela-Lima A, Alessi AC, Daleck CR, Salgado BS, Fernandes CG, Sobral RA, Amorim RL, Gamba CO, Damasceno KA, Auler PA, Magalhães GM, Silva JO, Raposo JB, Ferreira AMR, Oliveira LO, Malm C, Zuccari DAPC, Tanaka NM, Ribeiro LR, Campos LC, Souza CM, Leite JS, Soares LMC, Cavalcanti MF, Fonteles ZGC, Schuch ID, Paniago J, Oliveira TS, Terra EM, Castanheira TLL, Felix AOC, Carvalho GD, Guim TN, Garrido G, Fernandes SC, Maia FCL, Dagli MLZ, Rocha NS, Fukumasu H, Grandi F, Machado JP, Silva SMMS, Bezerril JE, Frehse MS, Almeida ECP, Campos CB. Consensus for the Diagnoses, Prognosis and Treatment of Canine Mammary Tumors. *Brazilian J Vet Pathol* 2011; 4:153-180.
- Cassali GD, Lavallo GE, Ferreira E, Estrela-Lima A, Nardi AB de, Ghever C, Sobral RA, Amorim RL, Oliveira LO, Sueiro FAR, Beserra HEO, Bertagnolli AC, Gamba CO, Damasceno KA, Campos CB, Araujo MR, Campos LC, Monteiro LN, Nunes FC, Horta RS, Reis DC, Luvizotto MCR, Magalhães GM, Raposo JB, Ferreira AMR, Tanaka NM, Grandi F, Ubukata R, Batschinski K, Terra EM, Salvador RCL, Jark P, Delecrodi JER, Nascimento AN, Silva DN, Silva LP, Ferreira KCRS, Frehse MS, Di Santis GW, Silva EO, Guim TN, Kerr B, Cintra PP, Silva FBF, Leite JS, Mello MFV, Ferreira MLG, Fukumasu H, Salgado BS, Torres R. Consensus for the Diagnosis, Prognosis and Treatment of Canine Mammary Tumors - 2013. *Brazilian J Vet Pathol* 2014; 7:38-46.
- Cintra PP, Paula CAT, Calazans SG, Souza JL, Magalhães GM. Reclasseificação e determinação do tipo histológico predominante em neoplasias mamárias caninas do Hospital Veterinário da Universidade de Franca nos anos de 2010 a 2012. *Enciclopédia Biosfera, Centro Científico Conhecer* 2014; 10:2067.

- Elston CW, Ellis IO. Assessment of histological grade. ELSTON CW., ELLIS IO. Eds. Systemic Pathology. The breast. London: Churchill Livingstone, 1998, 365-384.
- Feliciano MAR, Silva AS, Peixoto RVR, Galera PD, Vicente, WRR. Estudo clínico, histopatológico e imunoistoquímico de neoplasias mamárias em cadelas. *Arq Bras Med Vet Zootec* 2012; 64:1094-1100.
- Goldschmidt M, Peña L, Zappulli V. Tumors of the mammary gland. In: MEUTEN, D.J. Tumors in domestic animals, 5.ed. Ames: Iowa State Press, p. 723-757, 2017.
- Goldschmidt M, Peña L, Rasotto R, Zappuli V. Classification and grading of canine mammary tumors. *Vet Pathol* 2011; 48:117-131.
- Guarino M, Tosoni A, Nebuloni M. Direct contribution of epithelium to organ fibrosis: epithelial-mesenchymal transition. *Human Pathol* 2009; 40:1365-76.
- Hanahan DE, Weinberg RA. The hallmarks of cancer. *Cell* 2000; 100:57-70.
- Hasebe T, Tsuda H, Hirorashi S, Shimosato Y, Iwai M, Imoto S, Mukai K. Fibrotic focus in invasive ductal carcinoma: an indicator or high tumor aggressiveness. *Jpn J Cancer Res* 1996; 87:385-394.
- Hasebe T, Mukai K, Tsuda H, Ochiai A. New prognostic histological parameter of invasive ductal carcinoma of the breast: clinicopathological significance of fibrotic focus. *Pathol Int* 2000; 50:263-272.
- Itoh T, Uchida K, Ishikawa K, Kushima K, Kushima E, Tamada H, Moritake T, Nakao H, Shii H. Clinicopathological survey of 101 canine mammary gland tumors: Differences between small-breed dogs and others. *J Vet Med Sci* 2005; 67:345-347.
- Jensen-Jarolim E, Fazekas J, Singer J, Hofstetter G, Oida K, Matsuda H, Tanaka A. Crosstalk of carcino embryonic antigen and transforming growth factor- β via their receptors: comparing human and canine cancer. *Cancer Immunol Immunother* 2015; 64:531-537.
- Kalluri R. Basement membranes: structure, assembly and role in tumor angiogenesis. *Nature Rev Cancer* 2003; 3:422-433.
- Kalluri R, Zeisberg M. Fibroblasts in cancer. *Nature Rev Cancer* 2006; 6:392-40.
- Klopfleisch R, Von Euler H, Sarli G, Pinho SS, Gärtner F, Gruber AD. Molecular Carcinogenesis of Canine Mammary Tumors: News From an Old Disease. *Vet Pathol* 2011; 48:98-116.
- Lana SE, Rutteman GR, Withrow SJ, Macewen EG. Tumors of the mammary gland. In: Withrow SJ, Macewen EG. *Small Animal Clinical Oncology*. 5 th ed. St Louis: Elsevier Saunders, 2013, 619-636.
- Liu B, Zheng Y, Huang G, Lin M, Shan Q, Lu Y, Tian W, Xie X. Breast Lesions: Quantitative Diagnosis Using Ultrasound Shear Wave Elastography - A Systematic Review and Meta-Analysis. *Ultrasound Med Biol* 2016; 42:835-847.
- Mcpaill LD, Robinson SP. Intrinsic susceptibility MR Imaging of Chemically Induced Rat Mammary Tumors: Relationship to Histologic Assessment of Hypoxia and Fibrosis. *Radiology* 2010; 254:110-118.
- Misdorp W, Else RW, Hellmén E. Histological classification of mammary tumors of the dog and the cat. Armed Forces Institute of Pathology. Washington: 1999; 7:1-59,
- Moulton JE. 1990. Tumors of mammary gland. In: MOULTON, J. E (Ed) *Tumors in domestic animals*. 3rd ed. p. 518-552.
- Nardi AB, Rodaski S, Sousa RS, Costa TA, Macedo TR, Rodigheri SM, Rios A, Piekarz CH. Prevalence of neoplasms and kind of treatments in dogs seen in Veterinary Hospital at University Federal of Paraná. *Arch Vet Sci* 2002; 7:15-26.
- Oliveira LO, Oliveira RT, Loretti AP, Rodrigues R, Driemeier D. Aspectos epidemiológicos da neoplasia mamária canina. *Acta Sci Vet* 2003; 31:105-110.
- Oliveira Filho JC, Kommers GD, Masuda EK, Marques BMFPP, Figuera RA, Irigoyen LF, Barros CSL. Estudo retrospectivo de 1.647 tumores mamários em cães. *Pesq Vet Bras* 2010; 30:177-185.
- Owen LN. The TNM Classification of tumors in domestic animals. Geneva: World Health Organization; 1980.
- Queiroga FL, Raposo T, Carvalho MI, Prada J, Pires I. Canine Mammary Tumours as a Model to Study Human Breast Cancer: Most Recent Findings. *In vivo* 2011; 25:455-466.
- Solez K, Axelsen RA, Benediktsson H, Burdick JF, Cohen AH, Colvin RB et al. International standardization of criteria for the histologic diagnosis of renal allograft rejection: The Banff working classification of kidney transplant pathology. *Kidney International* 1993; 44:411-422.
- Soler M, Dominguez E, Lucas X, Novellas R, Gomes-Coelho KV, Espada Y, Agut A. Comparison between ultrasonographic findings of benign and malignant canine mammary gland tumours using B-mode, colour Doppler, power Doppler and spectral Doppler. *Res Vet Sci* 2016; 107:141-146.
- Sorenmo K. Canine mammary gland tumors. *Vet Clin North Am Small Anim Practice* 2003; 33:573-596.
- Sorenmo KU, Kristiansen VM, Cofone MA, Shofer FS, Breen AM, Langeland M, Mongil CM, Grondahl AM, Teige J, Goldschmidt MH. Canine mammary gland tumors; a histological continuum from benign to malignant; clinical and histopathological evidence. *Vet Comp Oncol* 2009; 7:162-172.
- Thannickal VJ, Toews GB, White ES, Lynch JP, Martinez FJ. Mechanisms of pulmonary fibrosis. *Annu Rev Med* 2004; 5:395-417.
- Van Den Eynden G G, Colpaert CG, Couvelard A, Pezzella F, Dirix LY, Vermeulen PB, Van Marck EA, Hasebe T. A fibrotic focus is a prognostic factor and a surrogate marker for hypoxia and (lymph) angiogenesis in breast cancer: review of the literature and proposal on the criteria of evaluation. *Histopathol* 2007; 51:440-451.
- Visan S, Balacescu O, Berindan-Neagoe I, Catoi C. In vitro comparative models for canine and human breast cancers. *Clujul Medical* 2016; 89:38-49.
- Wynn TA. Cellular and molecular mechanisms of fibrosis. *J Pathol* 2008; 214:199-210.

Masculinization of South American catfish (*Rhamdia quelen*) through dietary administration of 17 α -methyltestosterone[□]

Masculinización del pez Liso (Rhamdia quelen) mediante suministro dietario de 17 α -metiltestosterona

Masculinização do Jundiá (Rhamdia quelen) através da administração dietética de 17 α -metiltestosterona

Luciano A Weiss*, PhD; Jurandir J Bernardes Júnior, MSc; Claudia Machado, MSc; Alex P de Oliveira Nuñez, PhD.

Laboratório de Biologia e Cultivo de Peixes de Água Doce, Departamento de Aquicultura, Centro de Ciências Agrárias, Universidade Federal de Santa Catarina.

(Received: September 1, 2016; accepted: December 12, 2017)

doi: 10.17533/udea.rccp.v31n4a07

Abstract

Background: Production of monosex cultures of females is desirable in commercial aquaculture of certain species due to their higher growth rate. Ideally, females should be free of exogenous hormones. The initial step to produce hormone-free all-female offspring is masculinization of normal females to create sex reversed animals, called neomales, which are then be bred with normal females obtaining all-female offspring. **Objective:** To masculinize *Rhamdia quelen* fry by adding 17 α -methyltestosterone (MT) hormone to the feed. **Methods:** Larvae of *R. quelen* were fed diets supplemented with 60, 80, or 100 mg MT/kg feed for 21 days. A control group was fed the same diet free of MT. At 150 days post-hatching, 30 fish of each treatment group were euthanized to evaluate gonadal changes using histological techniques. **Results:** MT significantly affected the differentiation of female gonads in the 60 and 80 mg MT/kg feed groups. Sex reversal was observed in all MT treatment groups, with 50, 40, and 20% neomales produced with 60, 80, and 100 mg MT/kg feed, respectively. Intersex gonads were observed only in the masculinization treatment groups. Inhibitory effects on gonadal development of females and males were observed at the highest MT doses. **Conclusion:** Dietary administration of MT effectively masculinizes *R. quelen* fry; however, the lowest dose of 60 mg/kg feed is recommended, since higher doses have inhibitory effects on gonadal development in both sexes.

Keywords: *histology, fish gonads, monosex culture, neomales, sex reversal.*

Resumen

Antecedentes: Debido a su mayor tasa de crecimiento, la producción de peces femeninos monosexo es deseable en acuicultura comercial de determinadas especies. Idealmente, las hembras deben estar libres de

□ To cite this article: Weiss LA, Bernardes JJ, Machado C, de Oliveira AP. Masculinization of South American catfish (*Rhamdia quelen*) through dietary administration of 17 α -methyltestosterone. Rev Colomb Cienc Pecu 2018; 31(4):304-314.

* Corresponding author: Luciano Augusto Weiss. Laboratório de Biologia e Cultivo de Peixes de Água Doce, Departamento de Aquicultura, Centro de Ciências Agrárias, Universidade Federal de Santa Catarina. Rodovia Francisco Thomaz dos Santos, nº 3532. CEP: 88066-260. Florianópolis, SC, Brasil. E-mail: luciano@lapad.ufsc.br

hormonas exógenas. El paso inicial para generar descendencia femenina libre de hormonas es la masculinización de hembras genéticas para producir animales sexualmente revertidos, llamados neomachos, los cuales se aparean luego con hembras genéticas para producir descendencia femenina. **Objetivo:** Masculinizar larvas de *Rhamdia quelen* con 17 α -metiltestosterona (MT) incorporada en el alimento. **Métodos:** Larvas de *R. quelen* fueron alimentadas con dietas suplementadas con 60, 80 y 100 mg de MT/kg de alimento durante 21 días. Un grupo control recibió la misma dieta, sin MT. A los 150 días pos-eclosión, 30 peces de cada tratamiento fueron eutanasiados para evaluación gonadal mediante técnicas histológicas. **Resultados:** La MT afectó significativamente la diferenciación de las gónadas femeninas en las dosis de 60 y 80 mg MT/kg de alimento. El cambio de sexo se observó en los tratamientos con las dosis de 60, 80 y 100 mg MT/kg alimento, con 50, 40 y 20% de neomachos, respectivamente. En los tratamientos de masculinización se observaron gónadas intersexuales. En las dosis más altas de MT se observó inhibición del desarrollo gonadal de hembras y machos. **Conclusiones:** El suministro dietario de MT masculinizó las larvas de *R. quelen*. Se recomienda usar 60 mg/kg, ya que dosis mayores tienen efectos inhibidores en el desarrollo gonadal para ambos sexos.

Palabras clave: cultivo monosexo, gónadas de peces, histología, neomachos, reversión sexual.

Resumo

Antecedentes: O cultivo monossexo feminino é desejável na aquicultura comercial de determinadas espécies devido à maior taxa de crescimento. Idealmente, as fêmeas devem ser livres de hormônios exógenos. O passo inicial para gerar descendências femininas livres destes hormônios é a masculinização de fêmeas normais para produzir animais revertidos sexualmente, os chamados neomachos. Os neomachos podem então ser cruzados com fêmeas normais para a produção de descendências femininas. **Objetivo:** Masculinizar larvas de *R. quelen* utilizando o hormônio 17 α -metiltestosterona (MT) incorporado no alimento. **Métodos:** Larvas de *R. quelen* foram alimentadas com dietas suplementadas com MT nas doses de 60, 80 ou 100 mg/kg de alimento durante 21 dias. Um grupo controle foi alimentado com dieta similar livre de MT. Aos 150 dias pós-eclosão, 30 peixes de cada grupo de tratamento foram eutanasiados para avaliação gonadal através de técnicas histológicas. **Resultados:** O uso de MT afetou significativamente a diferenciação das gónadas femininas nas doses 60 e 80 mg/kg de alimento. A reversão sexual foi observada em todos os grupos tratados com MT, gerando 50, 40 e 20% de neomachos nas doses 60, 80 e 100 mg MT/kg de alimento, respectivamente. Gónadas intersexuais foram observadas somente nos tratamentos masculinizantes. Nas maiores doses de MT, efeitos inibitórios de desenvolvimento gonadal foram observados em fêmeas e machos. **Conclusão:** A administração dietética de MT efetivamente masculinizou larvas de *R. quelen*. No entanto, a dose mais baixa de 60 mg/kg de alimento é recomendada devido aos efeitos inibitórios das doses mais elevadas de MT no desenvolvimento gonadal de ambos os sexos.

Palavras-chave: cultivo monossexo, gónadas de peixe, histologia, neomachos, reversão sexual.

Introduction

Production of monosex fish is highly desirable for many species of commercial interest, such as *Oreochromis* and some salmonids, mainly due to size differences between sexes at maturity or to undesired reproduction during the production cycle (Dunhan, 2004). Monosex fish populations are typically obtained by sex reversal, which can be induced by temperature (Baroiller *et al.*, 1999) or by hormonal administration. Hormones can be applied via the diet, by bath immersion, and injections or implants (Pandian, 2013). Dietary supplementation with hormones is a low-cost method for sex reversal, and is widely used in species with a labile period (period in which sex cells are totipotential) after the first feeding (Pandian, 2013).

However, the use of hormones, such as steroids, is controversial for human and environmental health, and many European countries have banned it for farmed fish (Desprez *et al.*, 2003; El-Sayed, 2006). Consequently, monosex populations may also be induced indirectly by the combined use of hormones and mating strategies. This two-stage method of sex reversal has been implemented for the commercial culture of fish, such as salmonids (Hunter *et al.*, 1983; Feist *et al.*, 1995), to avoid direct application of hormones to species raised for human consumption.

The stages to produce hormone-free female offspring involve using hormones to directly masculinize females, followed by performance tests to identify masculinized females, known as neomales.